


UCSU6/3.10/4  
o.1

Colorado  
State  
University

Animal Reproduction Laboratory  
Bulletin No. 04

COLORADO STATE PUBLICATIONS LIBRARY  
UCSU6/3.10/4 local  
McKinnon, A. O./Equine reproductive ultr



3 1799 00014 0442



# EQUINE REPRODUCTIVE ULTRASONOGRAPHY

A. O. McKinnon, E. L. Squires and B. W. Pickett  
Animal Reproduction Laboratory  
Colorado State University  
Fort Collins, Colorado 80523

September 1988

## GILBERT C. VAN CAMP, JR.

(1921-1988)

This bulletin, "Equine Reproductive Ultrasonography", is in memory of Gilbert C. Van Camp, Jr., businessman, philanthropist, Arabian horse breeder, fisherman and gentleman. Mr. Van Camp was owner of Van Camp Arabians, Long Beach, California, and a native Californian. As a young man he worked in the Van Camp seafood company, but still had time to develop an interest in horses and game birds. It was during this period that he learned to fish commercially and for pleasure. After attending Occidental College he served in the Coast Guard during World War II. Upon returning from World War II, he entered the family business and later became president of the company then known as *Chicken of the Sea*. Under his leadership, the company expanded and later became a part of *Ralston-Purina*. His hobby of videotaping Arabian horses, particularly mares and babies, stimulated his interest in developing a purebred herd of Russian and Polish Arabians. In 1980 he purchased TJS Georgie Girl, 1978 National Champion Halter Mare, which was followed by a number of importations of straight Russian and Polish horses. At the time of his death, he had one of the finest herds of Russian and Polish mares in the U.S. His interest in breeding better horses led to development of a state-of-the-art facility for equine embryo transfer at his farm in California. In spite of his love for horses, he took time to fish from the *Vantuna II*, a modified tuna clipper that was designed and built to his specifications.

Gilbert was extremely generous in his support of the Boy's Club of San Pedro, the YMCA, various hospitals in southern California and the Laguna Art Museum.

The Animal Reproduction Laboratory, College of Veterinary Medicine and Biomedical Sciences wishes to express their sincere appreciation to Mr. Van Camp for his generous contributions to the Equine Sciences Program at Colorado State University.

# **EQUINE REPRODUCTIVE ULTRASONOGRAPHY**

A. O. McKinnon, E. L. Squires and B. W. Pickett  
Animal Reproduction Laboratory  
Colorado State University  
Fort Collins, Colorado 80523

September 1988

## ACKNOWLEDGEMENTS

It would not have been possible to gather the material for this bulletin without the outstanding contributions of our graduate students. Their dedication to our program is sincerely appreciated. A special thanks is extended to Dr. E. M. Carnevale for her valuable assistance with the completion of this bulletin. Secretarial assistance from Helen Mawhiney, Susan Lane and Sallie Varner was indispensable. We are grateful to the CSU Experiment Station, Van Camp Foundation, Abney Foundation, American Quarter Horse Association, Arabian Horse Registry of America Inc, Hamilton-Thorn, Ed H. Honnen and donations from Quarter Horse, Arabian and Thoroughbred breeders for funding for many of the studies reported herein.

**Note:** All income from the sale of this bulletin, above printing costs, will be used to aid in funding the equine teaching-research-service program.

# TABLE OF CONTENTS

LIST OF TABLES .....	v
LIST OF FIGURES .....	vii
GLOSSARY .....	xi
PREFACE .....	xiii
Chapter 1 Principles, Procedures, Equipment and Normal Ultrasonographic Anatomy and Artifacts .....	1
Chapter 2 Growth and Development of the Normal Fetus .....	11
Chapter 3 Management of Twins and Early Embryonic Death .....	21
Chapter 4 Uterine Pathology .....	31
Chapter 5 Follicular Dynamics Preceding and During Ovulation ....	41
Chapter 6 Formation and Development of the Corpus Luteum ....	51
Chapter 7 Ovarian Abnormalities .....	55

THE  
LIBRARY

## **LIST OF TABLES**

- Table 1-1. Ultrasonographic Equipment
- Table 1-2. Number of Mares Displaying Endometrial Folds in Relation to Day of Ovulation
- Table 2-1. Size of Vesicle (cm) During Early Gestation
- Table 2-2. Size of Embryo (cm) During Early Gestation
- Table 2-3. Efficacy of Real-Time Ultrasonography for Detection of Pregnancy (1982)
- Table 2-4. Incidence of False Negatives When Diagnosing Pregnancy by Ultrasonographic Scan (1982)
- Table 2-5. Efficacy of Real-Time Ultrasonography for Detection of Pregnancy (1983)
- Table 4-1. Ultrasonographic Evaluation of Uterine Fluid
- Table 4-2. Ultrasonographic Assessment of Uterine Fluid Quantity and Quality in 45 Mares After Parturition
- Table 4-3. Mean Interval from Parturition to Ovulation, and Pregnancy Rates for Control and Progestin-Treated Mares Bred During the First Post-Partum Ovulatory Period
- Table 4-4. Score Criteria Used to Diagnose Endometritis
- Table 4-5. Predictive Value of Individual Tests to Diagnose Endometritis Based on Two Levels of a Total Index Score for Endometritis
- Table 6-1. Percentage of Echogenic and Nonechogenic CL Visualized with Ultrasonography





## LIST OF FIGURES

- Figure 1-1. A linear array transducer. Width of the rectangular sound beam corresponds to length of the active or crystalized portion of the transducer.
- Figure 1-2. Ultrasonographic image from a linear-array scanner. (Arrows delineate 10 mm markers).
- Figure 1-3. A sector transducer. Sector scanners produce a sound beam that is triangular in shape because the sound waves radiate from a single point or source in the transducer.
- Figure 1-4. Ultrasonographic image from a sector scanner.
- Figure 1-5. Ultrasonographic image from a 3 MHz transducer. The lower frequency transducers (3 MHz) have less tissue resolution but greater tissue penetration.
- Figure 1-6. Diagrammatic view of the mare's reproductive tract.
- Figure 1-7. Ultrasonographic image of a uterine horn = cross-sectional image depicted from Figure 1-6 located at I.
- Figure 1-8. Ultrasonographic image of a mare's uterine body and cervix = longitudinal section located in Figure 1-6 at II.
- Figure 1-9. Ultrasonographic image of an ovary = cross-sectional image from Figure 1-6 at III.
- Figure 1-10. Ultrasonographic image of a uterine horn (arrows) from a mare in anestrus.
- Figure 1-11. Ultrasonographic image of a uterine body (arrow) from a mare in anestrus.
- Figure 1-12. Ultrasonographic image of a uterine horn from a mare in estrus. Presence of endometrial folds in this image is not an indication of endometritis. However, fluid (arrow) within the lumen may be a sign of uterine infection.
- Figure 1-13. Ultrasonographic image of the uterine body from a mare in estrus.
- Figure 1-14. Ultrasonographic image of a 20-day pregnancy with endometrial folding.
- Figure 1-15. Ultrasonographic image of enhanced through-transmission artifact beneath the image of an embryonic vesicle (arrow).
- Figure 1-16. Ultrasonographic refraction of an artifact beneath the edges of an ovary (arrow).
- Figure 1-17. Ultrasonographic image of specular reflection (arrow).
- Figure 1-18. Ultrasonographic image of reverberation artifact (arrow).
- Figure 1-19. Ultrasonographic image of shadowing (arrow).
- Figure 1-20. Ultrasonographic image of shadowing caused by fecal material on the transducer.
- Figure 2-1. Two unfertilized ova (UFO) on either side of a 4-cell equine embryo (arrow). Figure 2-1 through 2-6 were photographed at 200x magnification for ease of comparison.
- Figure 2-2. An 8-cell equine embryo.
- Figure 2-3. A 16-cell equine embryo.
- Figure 2-4. An early equine morula.
- Figure 2-5. An early equine blastocyst.
- Figure 2-6. An expanded equine blastocyst.
- Figure 2-7. Ultrasonographic image of a 10-day-old pregnancy.
- Figure 2-8. Ultrasonographic image of a 12-day-old pregnancy. Note the presence of dorsal and ventral specular reflection, which is artifactual (arrow).
- Figure 2-9. Ultrasonographic image of a 15-day-old pregnancy. The vesicle is still round.

- Figure 2-10. Ultrasonographic image of an 18-day-old pregnancy. The embryonic vesicle has stopped moving and become quite irregular.
- Figure 2-11. Ultrasonographic image of a 22-day-old embryo (delineated by electronic calipers). The heartbeat is commonly detectable about this time.
- Figure 2-12. Ultrasonographic image of a 25-day-old embryo. Note developing allantois (arrow).
- Figure 2-13. Ultrasonographic image of a 30-day-old pregnancy. Note developing allantois has pushed the embryo (arrow) dorsally, and regression of the yolk sac.
- Figure 2-14. Ultrasonographic image of a 38-day-old fetus. The yolk sac has almost regressed (arrow).
- Figure 2-15. Ultrasonographic image of a 45-day-old fetus. Note developing umbilical cord (arrow).
- Figure 2-16. Ultrasonographic image of a 55-day-old fetus in dorsal recumbency on the ventral uterine floor.
- Figure 2-17. Ultrasonographic image of a 26-day-old embryo with apposition of yolk sac and allantois giving the impression of a vertically oriented line.
- Figure 2-18. Ultrasonographic image of twin 14-day-old conceptuses in apposition. Note vertically oriented line (arrow).
- Figure 2-19. Position of vesicle in the uterus in relation to gestation. Adapted from (8).
- Figure 2-20. Growth characteristics of the conceptus. Adapted from (8).
- Figure 2-21. Ultrasonographic image of an abnormally developing fetal monster, day 65 post-ovulation. Note fluid accumulation within the head region (arrows).
- Figure 2-22. Ultrasonographic image of a fetus from the same mare as in Figure 2-21 at the same age of gestation. This embryo is believed to be developing normally.
- Figure 2-23. Ultrasonographic measurement of fetal eye size to estimate fetal age. Note characteristics of the eye from a 180-day developing fetus (arrow).
- Figure 2-24. Ultrasonographic measurement of fetal eye size to estimate fetal age. Note characteristics of the eye from a 230-day developing fetus (arrows).
- Figure 2-25. The relationship between day of gestation and size of fetal eye (length + width in cm with 95% confidence intervals for measurements;  $r = 0.92$ ).
- Figure 3-1. Twelve-day embryonic vesicles prior to separation.
- Figure 3-2. Separation of the vesicles in Figure 3-1 prior to crushing.
- Figure 3-3. Two 16-day embryonic vesicles fixed together at one corpus cornual junction.
- Figure 3-4. Destruction of one twin vesicle with pressure from a transducer.
- Figure 3-5. Twin 45-day pregnancies. Note presence of two umbilical cords (arrows).
- Figure 3-6. Small amount of fluid remaining at the corpus cornual junction after expulsion of the fetus.
- Figure 3-7. Early embryonic death. Note disruption of placental membranes, and increased echogenicity of fetal fluid.
- Figure 3-8. Early embryonic death. The embryo is being expelled through the cervix.
- Figure 3-9. Early embryonic death. Note resorption of fetal fluids.
- Figure 3-10. Fetal fluid protruding into the cervix.
- Figure 3-11. Apparent increase in size of the amnionic cavity and loss of embryo outline.
- Figure 3-12. Decreased fetal fluids. Fetus is in the uterine body instead of at the corpus cornual junction.
- Figure 3-13. Disrupted placental membranes (arrows).
- Figure 3-14. Apparent increase in size of the amnionic cavity with increased echogenicity of amnionic fluid.
- Figure 4-1. Grade I intrauterine fluid — white, strongly echogenic or hyperechogenic.
- Figure 4-2. Grade II intrauterine fluid — light grey, semi-echogenic or hyperechogenic.
- Figure 4-3. Grade III intrauterine fluid — dark grey, hypoechogenic; few hyperechoic foci suspended in an anechoic medium.

- Figure 4-4. Grade IV intrauterine fluid — black, anechoic.
- Figure 4-5. Multiple uterine cysts at the corpus cornual junction.
- Figure 4-6. Multiple, apparently compartmentalized, cysts in the uterine body surrounded by grade II uterine fluid.
- Figure 4-7. Hyperechogenic reflections slightly cranial to the cervix, characteristic of air.
- Figure 4-8. Hyperechogenic reflections due to air in the uterine horn.
- Figure 4-9. Ultrasonographic image of a hyperechogenic body in the mare's uterus (arrow). The echo shadow is indicative of dense tissue such as fetal bone.
- Figure 5-1. Ultrasonographic characteristics of an anestrous ovary (ovary delineated by arrows).
- Figure 5-2. Ultrasonographic characteristics of multiple follicles in an ovary of a mare in transitional estrus.
- Figure 5-3. Ultrasonographic characteristics of small follicles in an ovary of a mare in early diestrus.
- Figure 5-4. Ultrasonographic characteristics of follicles in an ovary of a mare during late diestrus.
- Figure 5-5. Ultrasonographic characteristics of a large preovulatory follicle.
- Figure 5-6. Ultrasonographic characteristics of an irregularly-shaped preovulatory follicle.
- Figure 5-7. Ultrasonographic characteristics of thickening of the follicular wall (arrow) as sometimes seen prior to ovulation.
- Figure 5-8. Echogenic debris (arrow) in follicular fluid.
- Figure 5-9. An echogenic nodule that is presumed to be the cumulus oophorous (arrow). This is occasionally detected on the follicular wall prior to ovulation.
- Figure 5-10. A follicle just prior to ovulation. Note the presence of a pronounced neck-like process of the follicular wall (arrow), and increased echogenicity of follicular fluid.
- Figure 5-11a. The process of ovulation recorded by ultrasonography. Preovulatory follicle 50 min prior to beginning of ovulation.
- Figure 5-11b. Preovulatory follicle 30 min prior to the beginning of ovulation. Note rent in dorsal follicular wall (arrow).
- Figure 5-11c. Preovulatory follicle 20 min prior to beginning of ovulation. Note decrease in follicular size.
- Figure 5-11d. Preovulatory follicle 15 min prior to beginning of ovulation.
- Figure 5-11e. The beginning of ovulation. Ovulation has been defined as a rapid decrease in follicular size.
- Figures 5-11 f to j. The process of ovulation occurred over approximately 60 seconds.
- Figure 6-1. Uniformly echogenic CL on day 0 (arrows).
- Figure 6-2. Uniformly echogenic CL on day 7 (arrows).
- Figure 6-3. Uniformly echogenic CL on day 14 (arrows).
- Figure 6-4. Gross characteristics of a CL that would be uniformly echogenic when visualized with ultrasonography.
- Figure 6-5. Corpus hemorrhagicum or central nonechogenic CL (arrow) on day 1 post-ovulation.
- Figure 6-6. Corpus hemorrhagicum on day 9 post-ovulation. The borders of the luteal structure are designated by arrows.
- Figure 6-7. Gross characteristics of a developing corpus hemorrhagicum, which appears as a centrally nonechogenic CL when visualized with ultrasonography.
- Figure 7-1. Ultrasonographic image of double preovulatory follicles.
- Figure 7-2. Ultrasonographic image of a triple ovulation (white arrows). All ovulations have tracts to the ovulation fossa (black arrows).
- Figure 7-3. Ultrasonographic image of an anovulatory, hemorrhagic follicle.
- Figure 7-4. Gross post-mortem characteristics of an anovulatory, hemorrhagic follicle. (Courtesy of Dr. V. E. Osborne).

- Figure 7-5. Ultrasonographic image of a luteinized, unruptured follicle. Note extreme irregularity and thickening of the follicular wall indicative of luteal tissue (arrow).
- Figure 7-6. Gross characteristics of a granulosa theca cell tumor.
- Figure 7-7. Ultrasonographic image of a granulosa theca cell tumor.
- Figure 7-8. Gross characteristics of a cyst or Hydatid of Morgagni. (Courtesy of Dr. V. E. Osborne).
- Figure 7-9. Ultrasonographic image of a Hydatid of Morgagni.
- Figure 7-10. Gross characteristics of a hydrosalpinx. (Courtesy of Dr. V. E. Osborne).

## GLOSSARY

**Anestrus** — Phase of the mare's reproductive cycle characterized by inactivity of the ovaries. Seen most commonly during the nonbreeding season.

**Artificial Insemination** — The deposition of semen into the uterus with instruments, rather than by copulation.

**Blastomere** — Individual undifferentiated cells of the early embryo.

**Capacitation** — The process by which spermatozoa become capable of fertilizing an ovum.

**Corpus Luteum** — A glandular mass in the ovary formed by an ovarian follicle that has matured and discharged its ovum. The corpus luteum secretes progesterone.

**Caudal** — Pertaining to the tail.

**Cranial** — Pertaining to the head.

**Diestrus** — A period of sexual quiescence occurring between consecutive estrous periods in the mare.

**Embryo** — The developing organism, beginning with the fertilized ovum and continuing to the fetal stage.

**Embryo Transfer** — Transfer of an embryo from a donor to a surrogate mare.

**Endometritis** — Inflammation of the endometrium (lining of the uterus).

**Estrus** — (Heat) That portion or phase of the estrous cycle of the mare characterized by willingness to accept the stallion.

**Fertility** — Measure of ability to produce offspring.

**Fertilization** — Union of the spermatozoon and oocyte.

**Fetus** — The developing organism after the major organs (e.g. heart) form and continuing to birth.

**Hormone** — A substance produced in one part of the body that has an effect in another part of the body.

**Luteotropic** — Stimulates the corpus luteum to secrete progesterone.

**Megahertz (MHz)** — One million sound waves per second.

**Oocyte** — Ovum.

**Ovum** — Egg, the female gamete.

**Pregnancy** — The condition of having a developing embryo or fetus in the body after union of an ovum and spermatozoon.

**Progesterone** — A hormone liberated by the corpus luteum, adrenal cortex and placenta whose function is to prepare the uterus for reception and development of the fertilized ovum.

**Spermatozoa** — Plural for spermatozoon.

**Spermatozoon** — A mature male germ cell which serves to fertilize the ovum.

**Transducer** — The portion of an ultrasonographic unit that contains piezoelectric crystals that vibrate to produce ultrasound.

**Transmural** — Through the wall of an organ.

**Ultrasound** — Mechanical radiant energy with a frequency greater than 20,000 cycles per second.

**Ultrasonography** — The use of ultrasound to allow visualization of deep structures of the body by recording reflections of echos of ultrasonic waves propagated and reflected by tissues.



## PREFACE

Few people predicted the impact that **ultrasonography** has had on the equine breeding industry. The ability to examine a mare's reproductive tract noninvasively with ultrasonography provides the opportunity to diagnose **pregnancy** earlier than with rectal palpation, effectively manage twins and detect impending early embryonic death (EED). However, ultrasonography should not be limited to these areas. Ultrasonography can be used to diagnose uterine pathology, such as intrauterine fluid, air, debris and cysts. In addition, ultrasonographic examination of the ovaries may aid in determining stage of estrous cycle, status of preovulatory follicles, development and morphologic assessment of the **corpus luteum** (CL) and in interpreting ovarian irregularities, such as anovulatory, hemorrhagic follicles or periovarian cysts.

The costs of equipment (Chapter 1) have resulted in a rather limited application of reproductive ultrasonography. Clients enthusiastically support use of ultrasonography to detect pregnancy. However, the same fee schedules for routine examination before and(or) after breeding are not currently accepted by the client. Perhaps another approach for practitioners involved with large numbers of broodmares would be a single fee per year per mare for use of equipment and a smaller fee per examination, whether the examination involved ultrasonography, palpation or both. If this philosophy was adopted, then a more logical approach to diagnosis and treatment of physiological and anatomical abnormalities of the mare's reproductive tract would be forthcoming. In addition, valuable information would be available from correlation of **fertility** data with normal and abnormal ultrasonographic observations.





## Chapter 1

# PRINCIPLES, PROCEDURES, EQUIPMENT AND NORMAL ULTRASONOGRAPHIC ANATOMY AND ARTIFACTS

### Principles

**Ultrasonography** is based on the principle of high frequency sound waves produced by electrical stimulation of piezoelectric crystals in a **transducer**. As sound waves are propagated through tissue, a proportion is reflected back to the transducer, converted to electrical impulses and displayed on a screen. Thus, the transducer is both a transmitter and receiver of sound. The magnitude of reflected sound waves is directly proportional to the difference in density at the interface, or junction, of two tissues. As sound waves go deeper into the body, weakening or attenuation occurs. In general, the greater the density of tissues, such as muscle and bone, the greater the impedance to propagation of sonographic waves, and the greater the strength of the echo produced. Fluid is an excellent medium for transmission of **ultrasonic** waves because it provides little impedance until the signal encounters an interface with an adjacent tissue of different density. Fluid-filled structures appear black or anechoic on the ultrasonic image. Both air and gas are poor propagators of ultrasonographic signals, and cause severe attenuation. For this reason, close contact of the transducer with tissue to be examined is essential. Very dense tissue such as the pelvis reflects most of the ultrasonic beam, and the image on the screen appears white. Other tissues are seen in various shades of gray depending upon their ability to reflect sound waves. The ultrasonic beam passes through tissue as a narrow band and scans only a narrow section.

Modern ultrasonographic instrumentation used for examination of the mare's reproductive tract are B-mode, real-time scanners. B-mode refers to brightness modality where the ultrasonographic image is a two-dimensional display of dots. Brightness of dots is pro-

portional to amplitude of returning echoes. When repeated signals are transmitted, received and processed, a continual visual image of tissues is produced, which permits observation of their structure and motion in real time (B-mode, real-time).


### Procedures

The procedure and precautions for intrarectal ultrasonographic examinations are similar to those for rectal palpation, and no additional restraint is required. The transducer should be protected by the examiner's hand to prevent trauma to the rectal wall, and the transducer should be well-lubricated. Care should be taken to avoid fecal material attaching to the transducer. After evacuating fecal material from the rectum, the probe is introduced and moved across the reproductive tract in the following pattern: uterine body, right uterine horn, right ovary, right uterine horn, uterine body, left uterine horn, left ovary, left uterine horn, uterine body then cervix. Good contact must exist between the transducer and rectal wall. Air in the rectum or a gas or fluid-filled loop of bowel will result in a distorted image. To minimize scanning errors, principally those of omission, it is recommended to conduct the same scanning procedure during each examination.

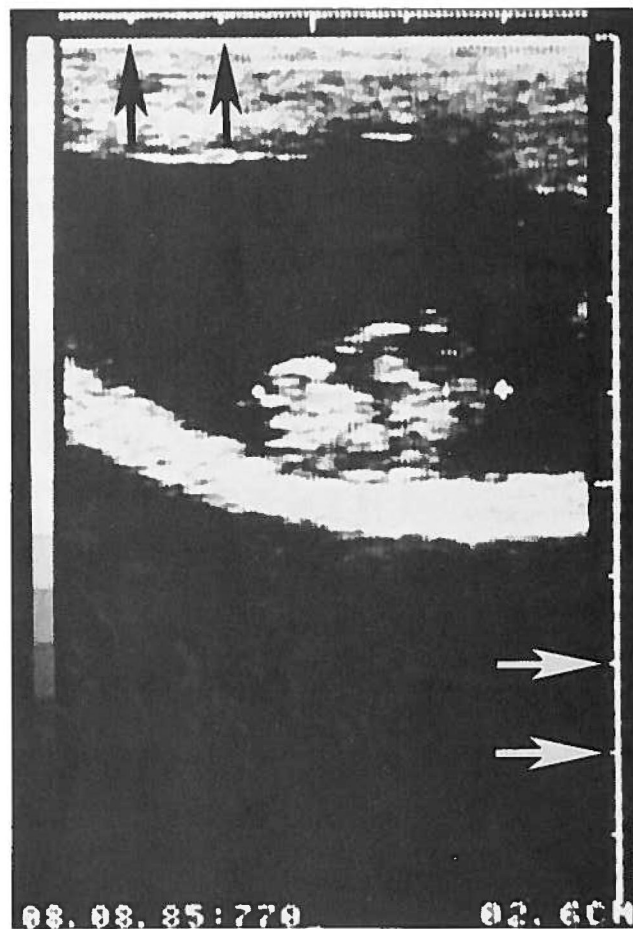
### Equipment

The two major types of real-time ultrasonographic transducers used for reproductive examination of the mare are linear and sectorial. Physical arrangement of the crystals within the transducer determines the pattern by which sound waves are propagated from the transducer. In linear-array scanners, the width of the

rectangular ultrasonic beam corresponds to length of the active or crystallized portion of the transducer (Figures 1-1 and 1-2). A linear-array transducer is oriented in the longitudinal plane with respect to the mare's body. Therefore, images of the cervix and uterine body are longitudinally-oriented and those of the uterine horn are cross-sectional. Images of tissues closest to the transducer are at the top of the screen. Sector scanners produce a beam that is triangular in shape, because sound waves radiate from a single point or source (Figures 1-3 and 1-4). The sound beam generally travels transversely to the mare's body and consequently, images of the cervix and uterine body are cross-sectional, while images of the horns are longitudinal or oblique.




**Figure 1-1.** A linear array transducer. Width of the rectangular sound beam corresponds to length of the active or crystallized portion of the transducer.



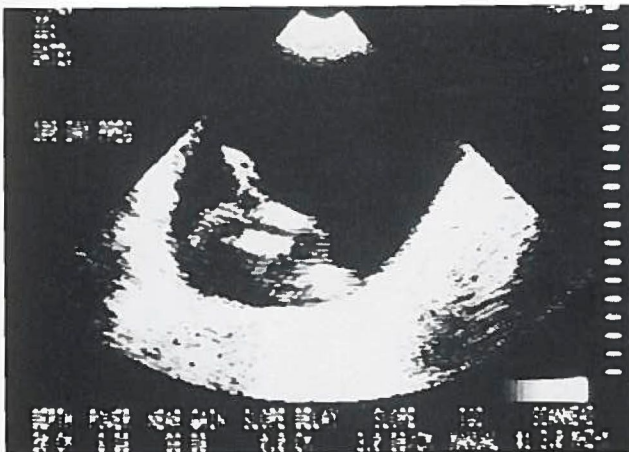
**Figure 1-2.** Ultrasonographic image from a linear-array scanner (arrows delineate 10 mm markers).

Resolution, which is the ability to detect small differences in tissue density, depends on frequency of sound waves. Higher frequency provides greater detail and lower frequency provides greater tissue penetration. Ultrasonographic frequencies are measured in megahertz (MHz; one hertz [Hz] = one sound wave/second). The lower frequency transducers (3 and 3.5 MHz) are suited for viewing larger structures at a greater distance from the transducer (Figure 1-5) than the 5 or 7.5 MHz transducers.

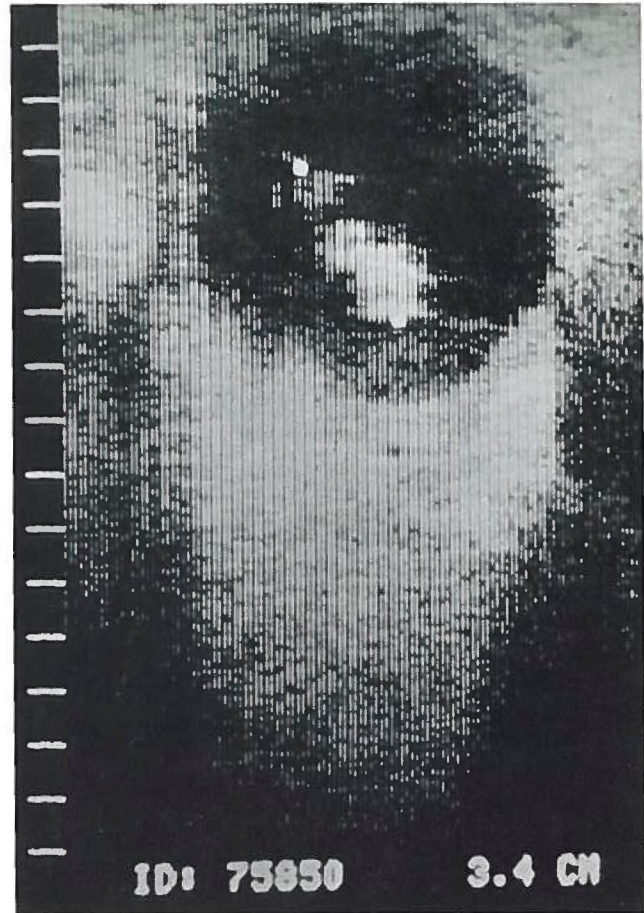
Higher frequency transducers (5 to 7.5 MHz) are most useful for detailed study of structures close to the transducer. All photographs of ultrasonographic images in this bulletin, except Figures 1-4 and 1-5, were recorded using a 5 MHz transducer from either the Corometrics 210 DX or the Equisonics 300 (Table 1-1).



**Figure 1-3.** A sector transducer. Sector scanners produce a sound beam that is triangular in shape because the sound waves radiate from a single point or source in the transducer.



**Figure 1-4.** Ultrasonographic image from a sector scanner.



**Figure 1-5.** Ultrasonographic image from a 3 MHz transducer. The lower frequency transducers (3 MHz) have less tissue resolution but greater tissue penetration.

Image size will vary with equipment. Five MHz transducers can be used to detect a conceptus on day 10 (1), follicles as small as 3 mm (0.12 inches; 2), and presence of a CL throughout most of **diestrus**(4,6). In comparison, a 3 or 3.5 MHz transducer can be used to detect a conceptus at about day 13 to 15, follicles approximately 6 to 8 mm (0.24 to 0.32 inches) in diameter, and the presence of a CL for 5 to 6 days post-ovulation(3). The principal uses of lower frequency transducers are to study an older **fetus** by either intrarectal or abdominal scanning or pathological conditions elsewhere in the body, such as liver abscesses.

Most modern ultrasonographic equipment enables the operator to freeze and(or) record images and automatically measure structures with a caliper-adjustment control. Some machines have split-frame capability with memory and various scanning frequencies (Table 1-1).

**Table 1-1. Ultrasonographic Equipment <sup>a</sup>**

	PieMedical Scanner 450	Corometrics 210 DX 260	Equisonics EQ 300	Wes Med WIC 50	Shimadzu SDL-32	Sono-Vet I	Sono-Vet II	Tokyo Keiki LS1000	Scan Mate	4000SL/Vet		
PRICE	\$11,000	\$11,500 (with one transducer)	\$24,500	\$13,500	\$7,995 for 3.2 MHz \$8,995 for 5 MHz	\$11,500 with video printer and 2 yr warranty	\$14,000	\$17,000	\$12,900	\$6,600	\$18,500	
WEIGHT	16 lb	17.6 lb	17 kg	38 lb	≥ 40 lb	15 lb	15 lb	22 lb	30 lb	3 lb 13 oz	50 lb	
SCANNING METHOD	Linear	Linear	Linear/ sector	Linear	Linear	Linear	Sector	Sector	Linear	Sector	Linear/ sector	
FREQUEN- CIES	5 MHz (3 & 7.5 can be used)	3.0, 5.0, 7.5 MHz	Linear= 3, 3.5, 5, 7.5 Sector= 3, 3.5, 5, 7.5	3.5, 5.0, 7.5 MHz	3.2 or 5.0 MHz	3.5, 4, 5, 7.5	2.5, 3.5, 5.0, 7.5	2.5, 3.5, 5.0, 7.5	3.5, 5, 7.5	3.5, 5, 7.5 variable configurations	Sect: 3.0, 5.5 Lin: 5.0	
GRAY LEVELS	32	16	16	64	64 (16 levels of color)	16	16	32	64	64	64	
FRAME RATE/SEC	60 or 30 fields/sec	15/30	15/30	24	~ 15/full screen focusing	30	19, 30	13, 19, 30	24	24 to 40	20/25	
VIDEO OUTPUT	Yes	Yes	Yes	Yes (video play-through mode)	VHS video recorder is optional (-\$700 without)	Yes	Yes	Yes (video playback with VCR in line measurements + calibrations)	Yes	No	Yes	
MONITOR SIZE	7"	5.5"	5.5" (optional 9" monitor)	9" (standard TV)	7"	5.5"	6"	6"	7"	2"	7"	
ALPHA- NUMERIC KEYBOARD	Yes	Numeric	Yes	Yes	Yes	Yes	Yes	Yes	Yes	Yes(2)/yes	No	Yes
CALIPERS/ AREA CIRC	Yes/yes	Yes/linear distance	Yes (2)/yes	Yes/yes	Yes/yes	Yes/No	Yes	Yes	Yes	Yes	No	Yes/no
REMOTE FREEZE	Yes	Yes	Yes	Yes	Yes	Yes			No	No	Yes	
PROBE SIZE	3" x .5 x .5"	Variable (5 MHz-56 mm length) small, streamline	Variable (Sector is small and in line)	5 & 7.5 MHz 5.5" x .5" - 1" x .5" 3.5 MHz 5" x 1" (dia) 4" (element size)	6" x .5" x .5"	11 diff. probes 2 equine rec- tal: 1) 8" length- traditional; 2) 8" length- sculptured; about 1/2 diameter	14 mm short-rectal probe, horizontally held with longitudinal scan of repro. tract. Transvaginal probe (30/60° angle) 5 MHz small ruminant probe	14 mm short-rectal probe, horizontally held with longitudinal scan of repro. tract. Transvaginal probe with 30/60° angle. 5 MHz small ruminant probe. NOTE: Doppler ready.	5 & 7.5 MHz 5.5" x .5" -1" x .5" 3.5 MHz 5" x 1" (dia) 4" (element size)	1.5" cylind. variable config.	Sect. 17 mm, 13 mm, 7 mm; Lin. ~ 4" x 1" x 1.5"	
ADDRESSES	El Medical PO Box 5375 Loveland, CO 80538 (303) 669-1793  Classical Medical Supply 8155 S US Hwy 1 Suite 4-409 Jupiter, FL 33477 (407) 746-9527	Corometrics Medical Systems, Inc. 61 Barnes Park Road North Wallingford, CT 800-243-3952		WesMed Medical Systems 18500 68th Avenue NE Box 3001 Bothell, WA 98041-3001 (206) 481-2296	Precision Veterinary Instruments, Inc. 14854 East Hinsdale Ave., Unit B Englewood, CO 80112 (303) 690-9403	Universal Medical Systems, Inc. 51 Smart Ave. Yonkers, NY 10704 (914) 423-1597		The Products Group PO Box 17086 Boulder, CO 80308 (303) 939-9380	Classical Medical Supply, Inc. 8155 S US Hwy 1 Suite 4-409 Jupiter, FL 33477 (407) 746-9527	Classical Medical Supply, Inc. 8155 S US Hwy 1 Suite 4-409 Jupiter, FL 33477 (407) 746-9527		

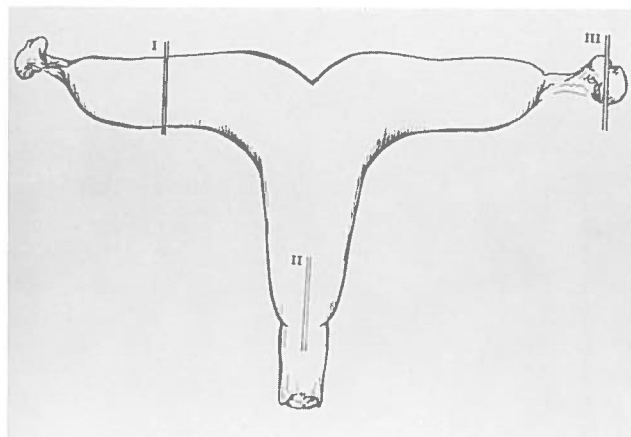
<sup>a</sup> Adapted from (6).

## Normal Anatomy — Uterus

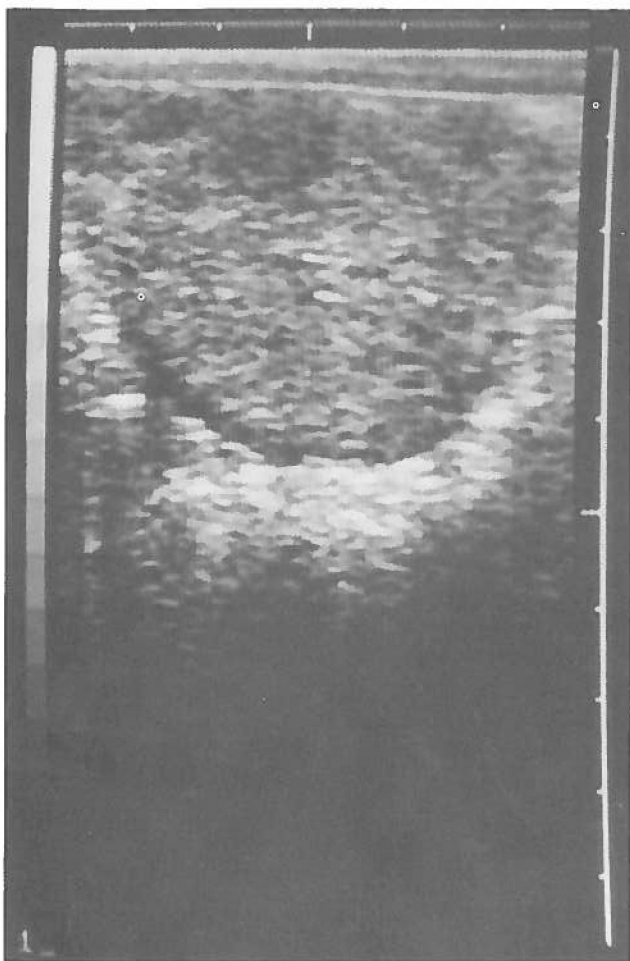
A thorough knowledge of ultrasonographic anatomy and understanding of dynamic changes in the uterus is essential for ultrasonographic evaluation of the mare's reproductive tract. The dynamic changes visualized with ultrasonography mirror the ovarian hormonal influences and aid in estimating reproductive potential.

The relationship between orientation of a linear-array transducer and orientation of the mare's repro-

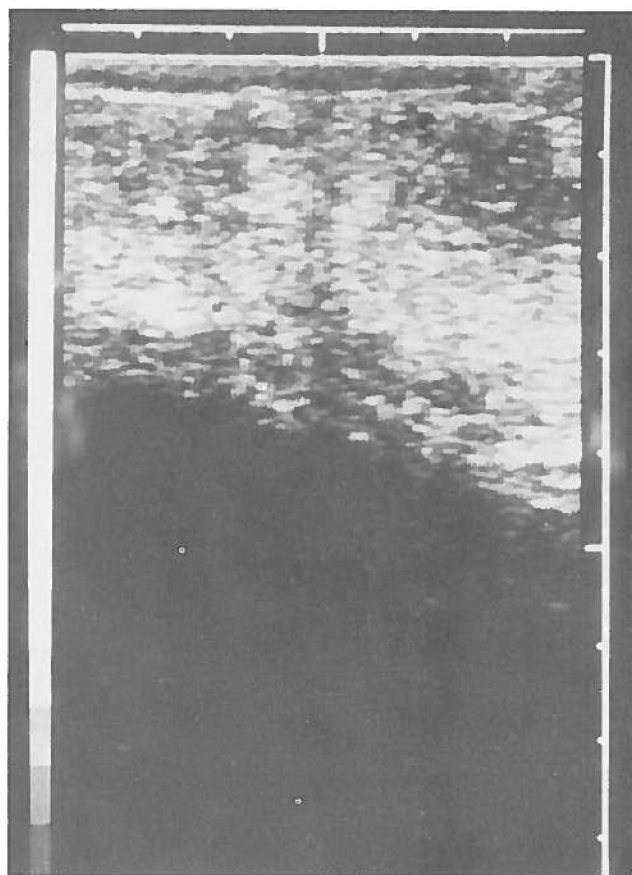
ductive tract is shown in Figures 1-6 to 1-9. Since the probe is generally held in a sagittal plane, images of the cervix and uterine body are longitudinally oriented with the cervix to the left of the ultrasonographic picture. The orientation of **cranial** on the right and **caudal** on the left of the screen remains constant throughout this bulletin. Uterine horns are seen in cross-section as the transducer is moved left or right. Depending upon orientation of the horn at a given examination, it may occasionally be necessary to manipulate the uterus in order to obtain a true cross-section.



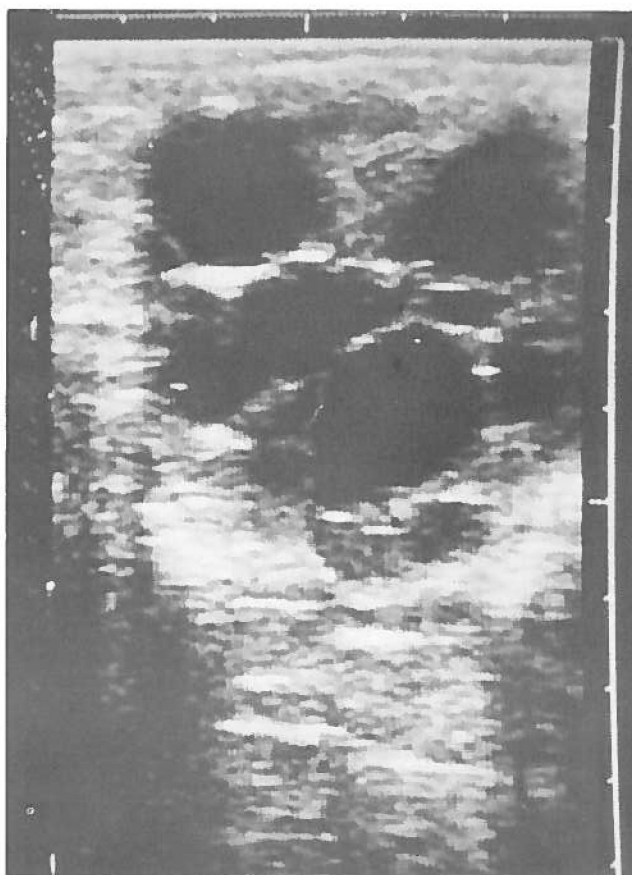
**Figure 1-6.** Diagrammatic view of the mare's reproductive tract.



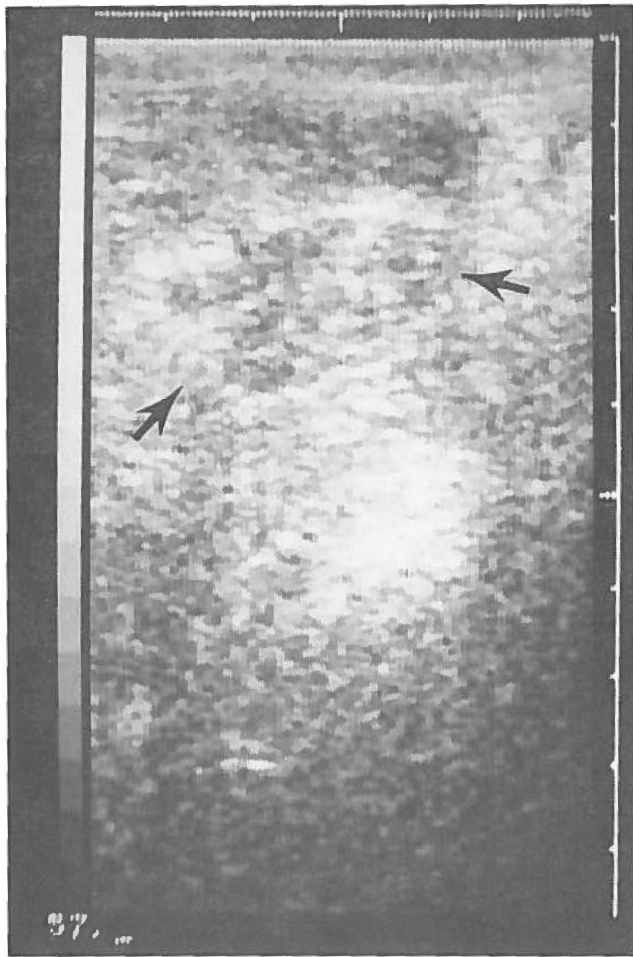
**Figure 1-7.** Ultrasonographic image of a uterine horn = cross-sectional image depicted from Figure 1-6 located at I.




**Figure 1-8.** Ultrasonographic image of a mare's uterine body and cervix = longitudinal section located in Figure 1-6 at II.



**Figure 1-9.** Ultrasonographic image of an ovary = cross-sectional image from Figure 1-6 at III.



**Figure 1-10.** Ultrasonographic image of a uterine horn (arrows) from a mare in anestrus.

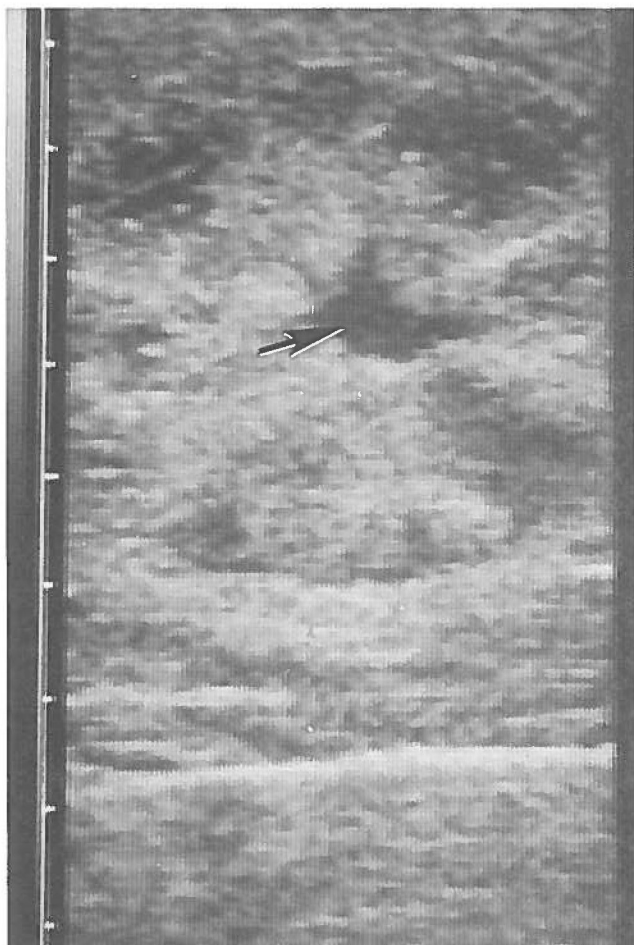

**Figure 1-11.** Ultrasonographic image of a uterine body (arrow) from a mare in anestrus.

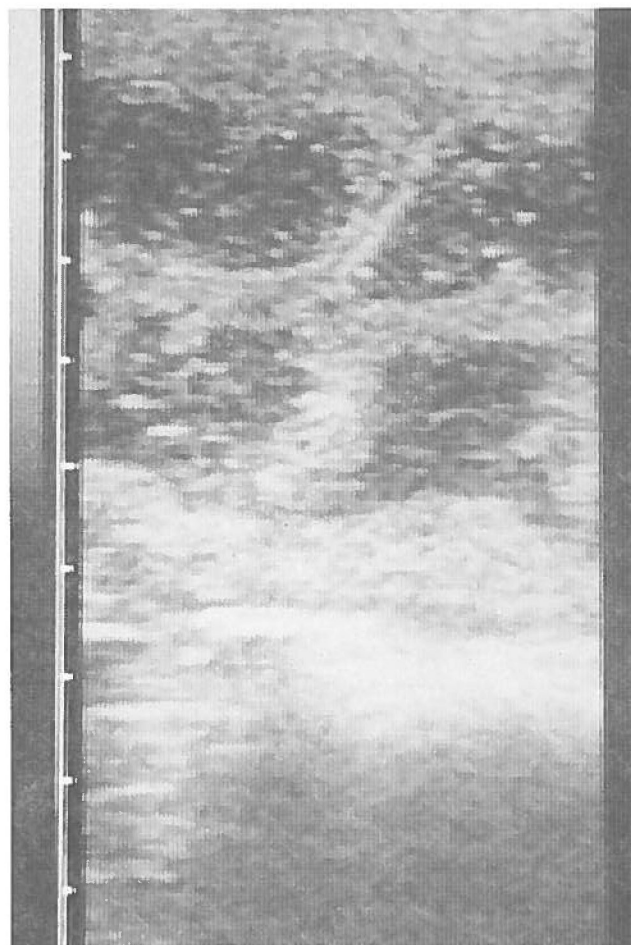
Ultrasonographic characteristics of the uterus during the anovulatory season, estrous cycle and **pregnancy** may often be differentiated. During **anestrus**, cross-section of uterine horns (Figure 1-10) and longitudinal section of uterine body (Figure 1-11) are often flat and irregular and may contour closely to surrounding abdominal organs (Figure 1-10 and 1-11). In **estrus**, uterine horns are well-rounded and both horns and body commonly have an interdigitated pattern of alternating echogenic and nonechogenic areas (Figures 1-12 and 1-13; 7). The areas of decreased echogenicity are the outer edematous portion of endometrial folds. The edema is due to effects of estrogen. This ultrasonographic pattern is reminiscent of a sliced orange. Endometrial folds, generally, are visible at the end of diestrus and become more prominent as estrus progresses, then decrease or disappear at approximately the time of ovulation which parallels estrogen production.

In a recent study (3), ultrasonographic properties of the uterus of 16 mares were determined each day of the cycle. Endometrial folds were not distinguishable during diestrus, and were prominent during estrus. The number of mares with images characteristic of

estrus increased gradually between day -7 (2/14; day of ovulation equals day 0), day -3 (11/16) and day -2 (10/16), then declined between days -1 and +1 (0/12). At our laboratory, endometrial folds are graded from 0 (no folds) to 3 (prominent endometrial folds). From a preliminary study(5) involving 100 mare cycles, endometrial folds were most prominent 1 or 2 days prior to ovulation (Table 1-2). A change to a lower grade could be used to predict ovulation. For example, a change from grade 3 to 0 was concomitant with ovulation. Practitioners should be aware of the extent of change in height of endometrial folds between diestrus and early estrus. Prominence of endometrial folds during estrus (Figures 1-12 and 1-13) should not be considered pathologic. Before this observation became common knowledge, some veterinary practitioners mistook prominent endometrial folds for endometritis, and unnecessarily treated mares. Ability to clearly observe endometrial folds depends upon transducer frequency and resolution of ultrasonographic equipment. On occasion, impending abortion is suspected when, during routine scanning for pregnancy, the embryonic vesicle is located in a uterus with prominent endometrial folds.



**Figure 1-12.** Ultrasonographic image of a uterine horn from a mare in estrus. Presence of endometrial folds in this image is not an indication of endometritis. However, fluid (arrow) within the lumen may be a sign of uterine infection.



**Figure 1-13.** Ultrasonographic image of the uterine body from a mare in estrus.

**Table 1-2. Number of Mares Displaying Endometrial Folds in Relation to Day of Ovulation**

Grade of endometrial folds	Time from ovulation (days)				
	-3	-2	-1	0 <sup>a</sup>	+2
0	73	27	33	64	95
1	3	17	24	24	4
2	18	35	27	12	1
3	6	21	16	0	0

<sup>a</sup>Day of ovulation = day 0.  
Adapted from (5).

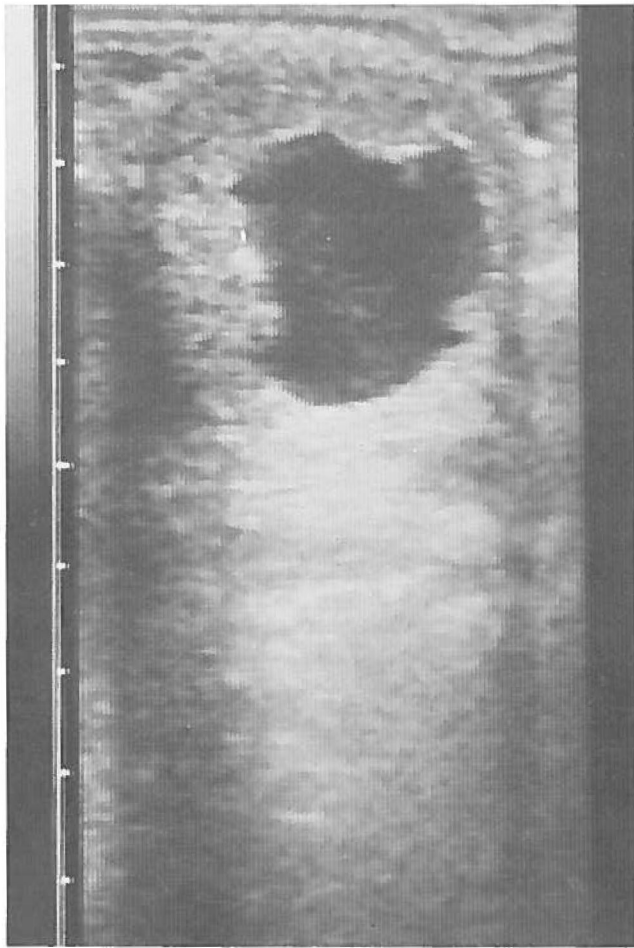
When a mare is in **diestrus**, individual endometrial folds are less distinct, or not discernible, and the echo texture is more homogeneous (Figure 1-7). When scanning the uterine body, the uterine lumen is often identified by a hyperechogenic white line. This is due to apposition of endometrial surfaces, and probably is caused by specular reflection(3). In general, during diestrus the entire uterine portion of the reproductive tract is well-circumscribed and defined.

Ultrasonographic images of the **pregnant** uterus are often identical to those of diestrus, with the exception that after day 16, endometrial folds may again appear.

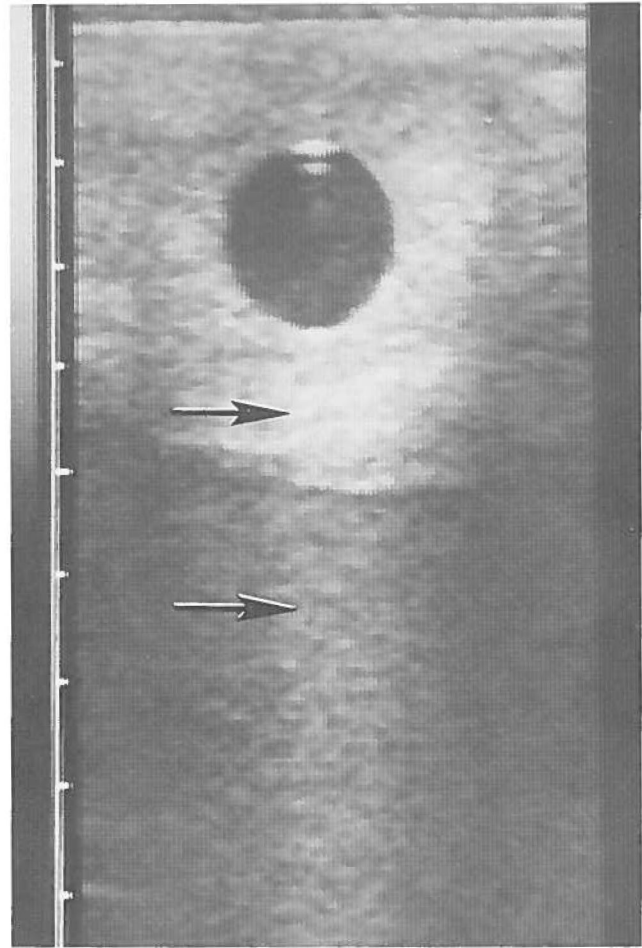
However, endometrial folds (Figure 1-14) are not as prominent as during estrus and may be associated with increasing uterine tone.

### Artifacts

Certain types or formations of tissue may cause waves to bend (refract), bounce back and forth, or re-echo (reverberate), or to become weakened or entirely blocked. These distortions may be mistaken for normal or pathological structures or changes. Fluid-filled structures such as follicles, embryonic vesicles and uterine cysts are common in the mare's reproductive tract and are responsible for the most notable artifacts. An intense echogenic formation beneath a fluid-filled structure is noted as an enhanced through-transmission artifact (Figure 1-15). This artifact is common beneath images of follicles and embryonic vesicles. Sound waves passing through fluid are not as attenuated as waves passing through adjacent tissue. Therefore, there is a brighter echo beneath the fluid-filled structure when compared to echos of corresponding depth beneath adjacent tissues. Intensity of



**Figure 1-14.** Ultrasonographic image of a 20-day pregnancy with endometrial folding.



**Figure 1-15.** Ultrasonographic image of enhanced through-transmission artifact beneath the image of an embryonic vesicle (arrow).

echos resulting from through-transmission can be reduced by proper adjustment of gain controls(2).

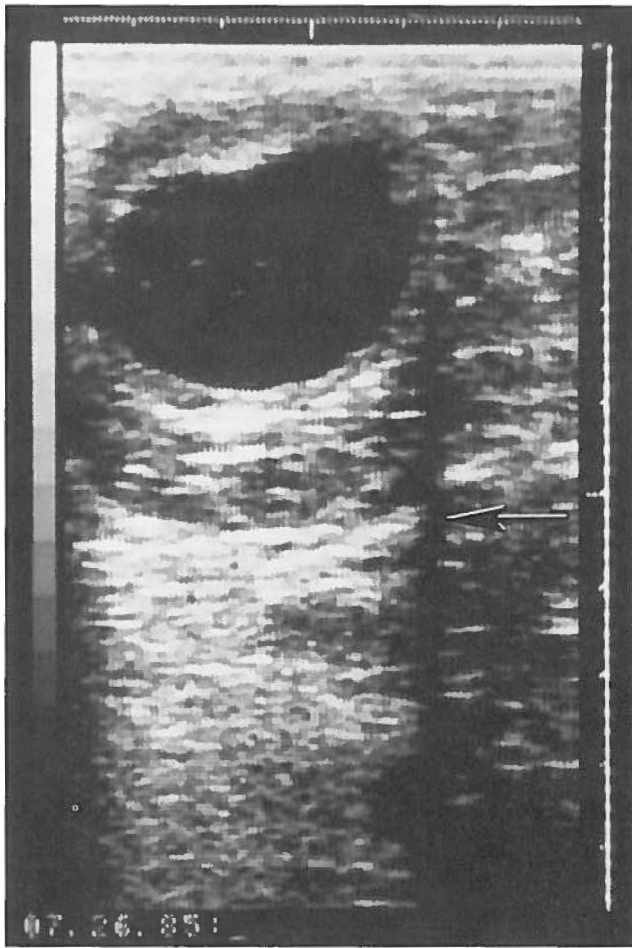
When a sonic beam strikes the side of a curved structural boundary at less than 90 degrees, it may bend or refract, causing a shadowing or lack of echo formation beyond the site of refraction. Refraction artifacts are especially common with images associated with follicles (Figure 1-16).

When a sonic beam strikes the upper and lower surface of a fluid-filled, spherical structure, a highly echogenic reflection is produced on the screen. This is termed specular reflection (Figure 1-17). Specular reflection was originally confused and incorrectly identified as being embryonic structures.

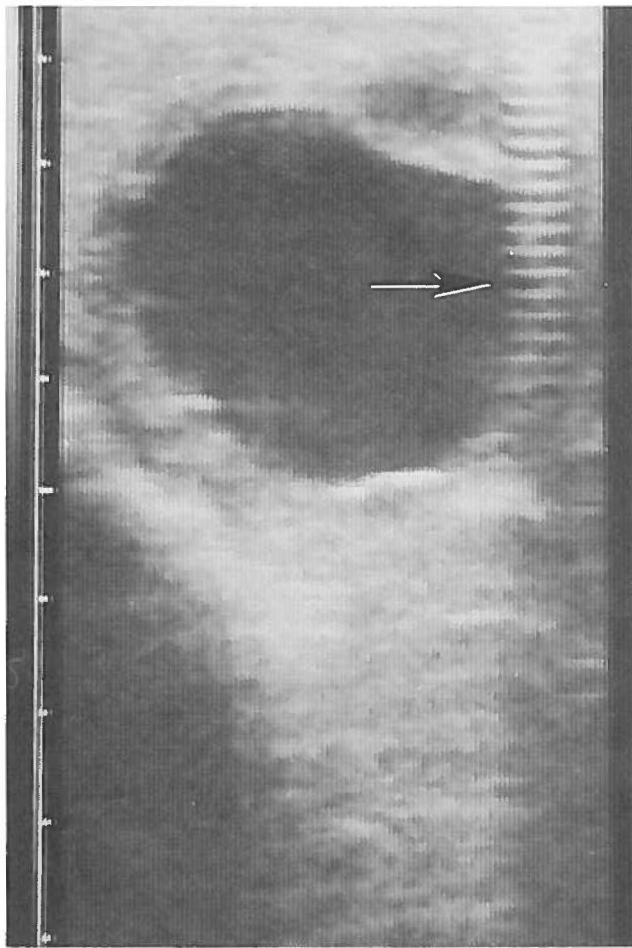
Reverberation artifacts (Figure 1-18) are commonly seen during intrarectal examination of the mare's reproductive tract because of gas-filled intestines beneath the area of interest. Reverberation occurs when sound waves encounter a highly reflective, gas-filled structure and bounce back and forth between intestine and transducer. Due to lag time of each returning echo as perceived by the transducer, bright echos are recorded on the screen at deeper and deeper, evenly spaced intervals.

Shadowing is an artifact characterized by lack of an echo beneath a very dense structure. This is caused by complete reflection or absorption of ultrasonographic waves. This artifact is uncommon in images of mares' reproductive systems because of the relative lack of tissues with density comparable to bone. A notable exception is the occurrence of shadowing beneath fetal bone after death of the fetus, and occasionally from foreign bodies such as a tip of a uterine culturette (Figure 1-19). The presence of fecal material on the transducer may also result in portions of the ultrasonographic image being obscured due to a shadowing artifact (Figure 1-20).

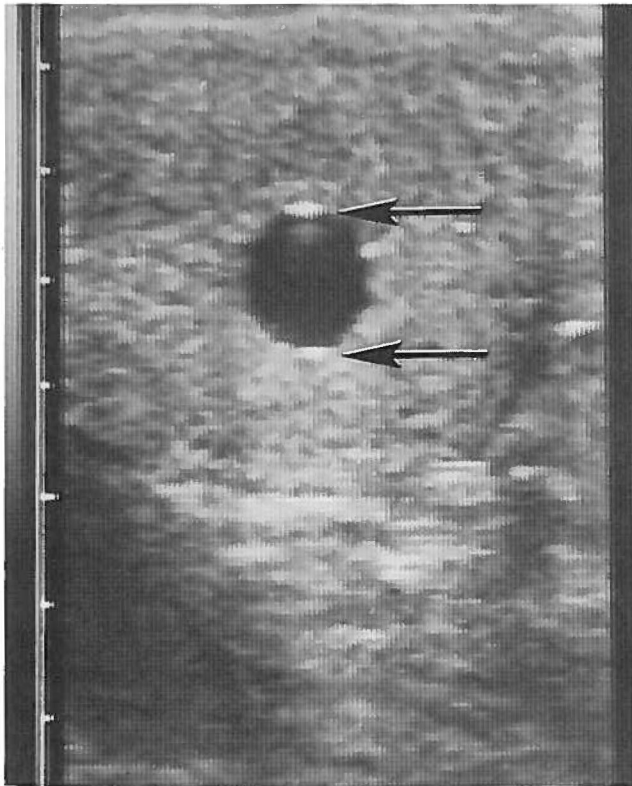




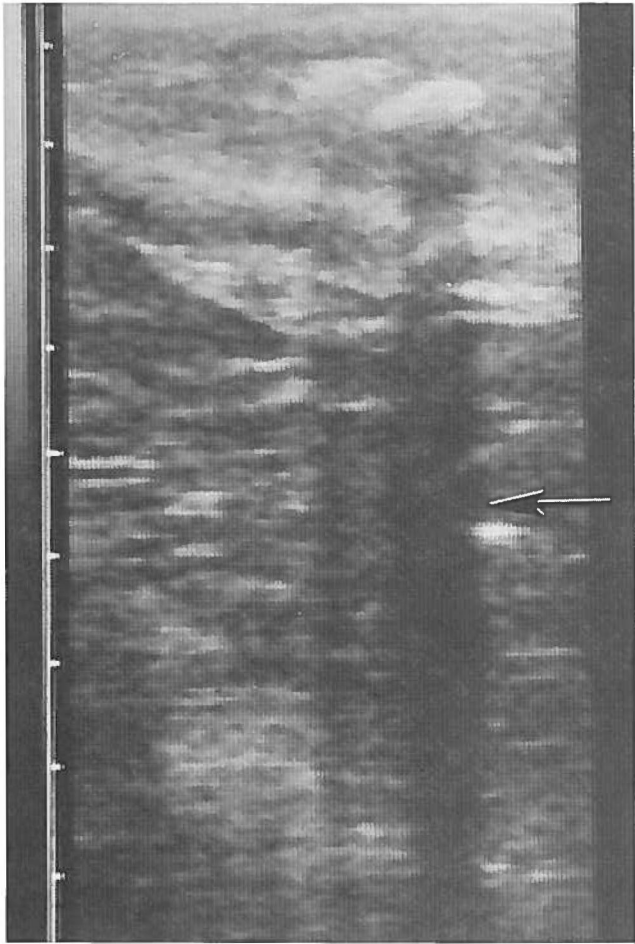
**Figure 1-16.** Ultrasonographic refraction of an artifact beneath the edges of an ovary (arrow).



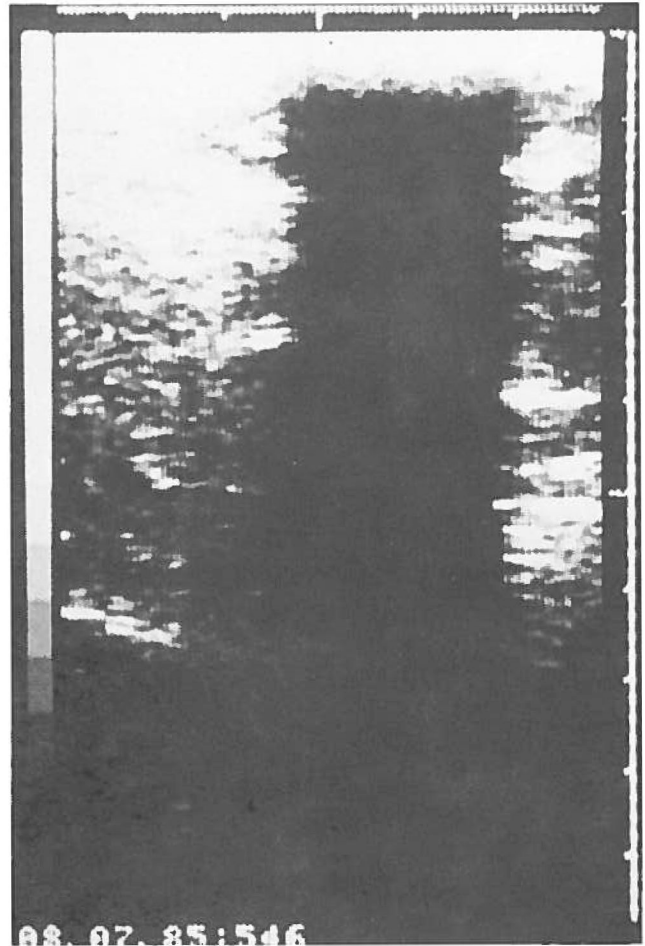**Figure 1-18.** Ultrasonographic image of reverberation artifact (arrow).



**Figure 1-17.** Ultrasonographic image of specular reflection (arrow).



**Figure 1-19.** Ultrasonographic image of shadowing (arrow).



**Figure 1-20.** Ultrasonographic image of shadowing caused by fecal material on the transducer.

### REFERENCES

1. Ginther, O.J. 1984. Ultrasonic evaluation of the reproductive tract of the mare: the single embryo. *J. Equine Vet. Sci.* 4:75-81.
2. Ginther, O.J. and R. A. Pierson. 1983. Ultrasonic evaluation of the reproductive tract of the mare; principles, equipment and techniques. *J. Equine Vet. Sci.* 3:195-201.
3. Ginther, O.J. and R. A. Pierson. 1984. Ultrasonic anatomy and pathology of the equine uterus. *Theriogenology* 21:505-515.
4. Ginther, O.J. and R. A. Pierson. 1984. Ultrasonic evaluation of the reproductive tract of the mare: ovaries. *J. Equine Vet. Sci.* 4:11-16.
5. McKinnon, A.O., E. L. Squires, E. M. Carnevale, L. A. Harrison, D. D. Frantz, A. E. McChesney and R. K. Shideler. 1987. Diagnostic ultrasonography of uterine pathology in the mare. *Proc. 33rd Ann. Conv. A.A.E.P.* pp.605-622.
6. McKinnon, A.O., E. L. Squires and J. L. Voss. 1987. Ultrasonic evaluation of the mare's reproductive tract: Part I. *Comp. Cont. Educ. Pract. Vet.* 9: 336-345.
7. McKinnon, A.O., E. L. Squires and J. L. Voss. 1987. Ultrasonic evaluation of the mare's reproductive tract: Part II. *Comp. Cont. Educ. Pract. Vet.* 9:472-482.

## Chapter 2

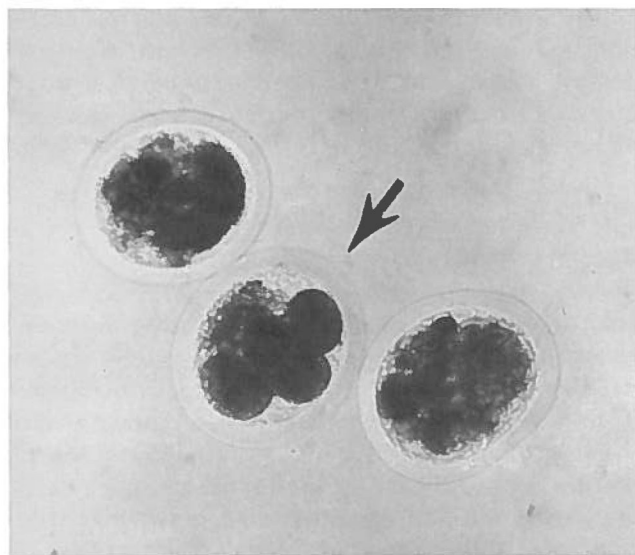
# GROWTH AND DEVELOPMENT OF THE NORMAL FETUS

### Introduction

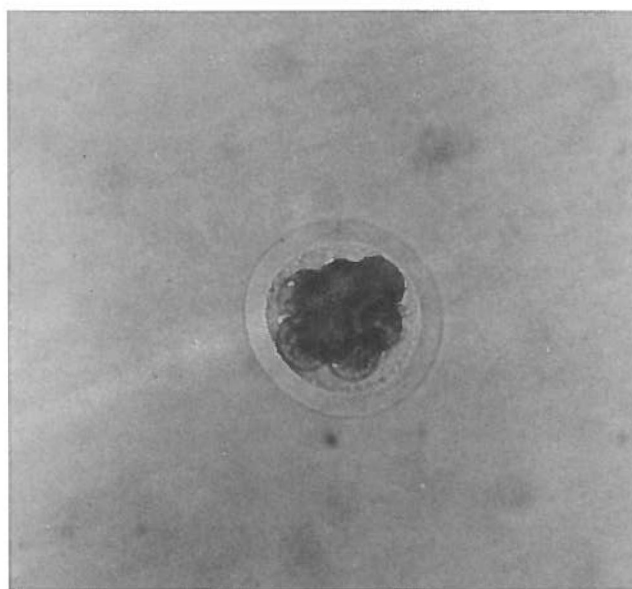
**Fertilization** occurs at the ampullary/isthmus junction of the oviduct, and requires a viable **oocyte** and **spermatozoon**(2). The first maternal recognition of pregnancy may be as early as 48 hrs post-ovulation in mares. This is associated with production of an immunosuppressive agent, a pregnancy-specific protein called early pregnancy factor (EPF). Early pregnancy factor has been detected in mice, sheep, humans(15) and mares(3), and holds exciting promise for future early detection of pregnancy and early embryonic death (EED).

Another event in maternal recognition of pregnancy occurs on or before 6 days post-ovulation. Fertilized ova are transported from the oviduct through the uterotubule junction and into the uterus by 5 to 6 days post-ovulation (12), while unfertilized ova (UFO; Figure 2-1) are generally retained in the oviduct (19). After

fertilization (day 0) and initial cleavage, each equine **blastomere** (cells produced by cleavage) divides approximately every 24 hours. We have found in our laboratory(11), based on oviductal flushes, that on day 2 post-ovulation, it is common to collect 4- to 8-cell embryos (Figures 2-1 and 2-2) and 8- to 16-cell embryos on day 3 (Figure 2-3). A 32- to 64-cell embryo is classified as a morula (Figure 2-4) and is the youngest developmental stage of embryo that can be harvested from the uterus. Generally, 6-day embryos are late morulas or early blastocysts (Figure 2-5). A blastocyst is recognized by development of a blastocele cavity within the embryo. The blastocele cavity, or yolk sac, is fluid-filled, and its continued expansion allows ultrasonographic determination of pregnancy as early as 10 days post-ovulation. Day-7 embryos (Figure 2-6) are generally expanded blastocysts. Embryos are generally visible to the naked eye by 7 to 8 days post-ovulation.



**Figure 2-1.** Two unfertilized ova (UFO) on either side of a 4-cell equine embryo (arrow). Figure 2-1 through 2-6 were photographed at 200x magnification for ease of comparison.



**Figure 2-2.** An 8-cell equine embryo.

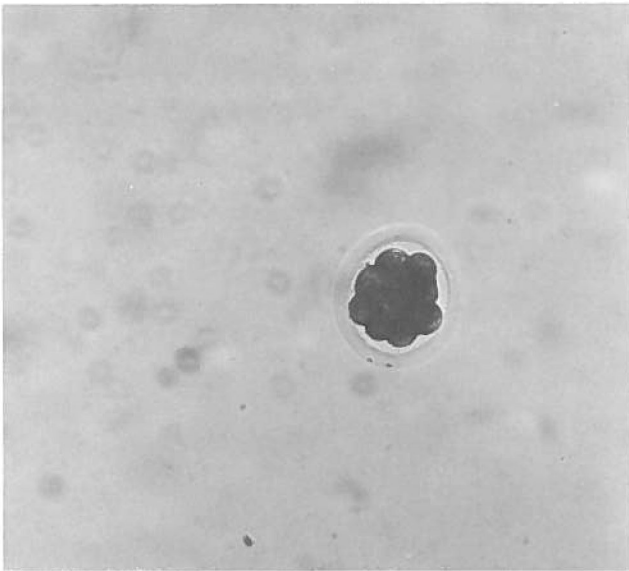


Figure 2-3. A 16-cell equine embryo.

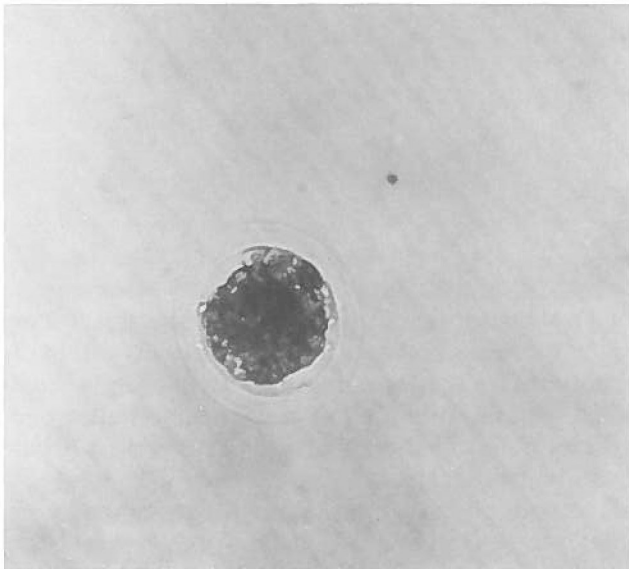


Figure 2-4. An early equine morula.

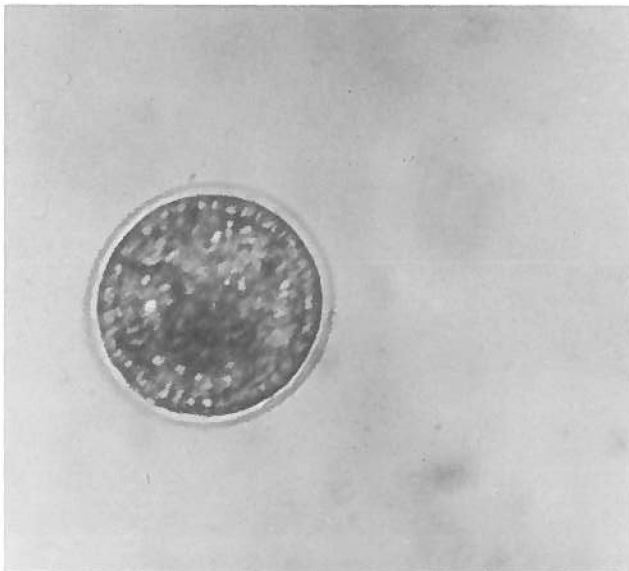


Figure 2-5. An early equine blastocyst.

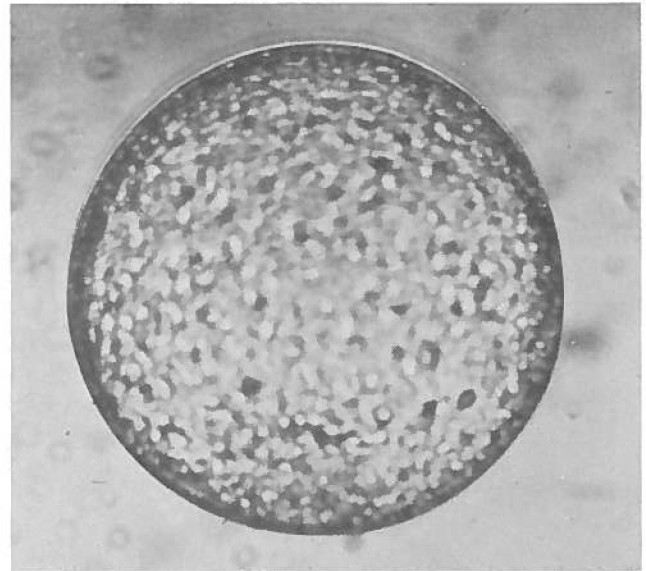


Figure 2-6. An expanded equine blastocyst.

A third event in maternal recognition of pregnancy occurs between 12 and 16 days. During this time, the conceptus is extremely mobile, and it is postulated that the conceptus prevents the action of prostaglandin F<sub>2</sub>-alpha that would normally destroy the corpus luteum (CL), resulting in a return to estrus(9,10). The conceptus may also produce substances that are **luteotropic**. For diagnosis of pregnancy at 10 to 12 days, a 5 or 7.5 MHz transducer is needed. However, due to embryonic loss in early pregnancy, it is inappropriate to discontinue the teasing program after initial examination for pregnancy. From a practical standpoint, the first examination could be postponed until approximately 18 to 20 days post-ovulation, thus eliminating scanning of mares that are destined to return to estrus. One exception would be scanning of mares that have a history of twinning or multiple ovulations. These mares should be examined at day 12 to 15 post-ovulation to most effectively manage manual embryonic reduction. Frequency of subsequent scans will depend on such factors as presence of twins, size and quality of the vesicle and embryo, availability of the mare and economics.

### Characteristics of the Conceptus

#### Days 10 to 17

Ultrasonographic scanning has resulted in an increase in our knowledge of dynamics of early pregnancy. Ultrasonographic images of the conceptus at various stages have been grouped together for convenience (Figures 2-7 to 2-18). It has recently been shown (4) that the early equine conceptus is highly mobile within the uterine lumen. Regardless of the side of entry into the uterus, the equine conceptus moves between the uterine horns and uterine body. Small yolk sacs (day 10) are spherical (Figure 2-7) and found most frequently in the uterine body (Figure 2-19). Transuterine movement occurs at intervals of less than 2 to 4 hrs (4).

Mobility begins to decrease by day 15, and after day 17, transuterine migration can no longer be detected (4,5). Thereafter, the vesicle is fixed at the caudal portion of one of the uterine horns. Mechanisms responsible for uterine migration of the conceptus have not been determined, but are presently being investigated. Extensive mobility of the early conceptus may be due to the spherical form and turgidity of the vesicle, and longitudinal arrangements of endometrial folds. Recently, researchers (10) have demonstrated that restriction of embryo movement resulted in pregnancy failure. These investigators suggested that pregnancy failure was caused by inability of the conceptus to reduce uterine secretion of prostaglandin F2-alpha.

When scanning for an early vesicle, the transducer should be moved slowly so the image or tissue slice visualized (2 to 3 mm wide) is not passed over the vesicle too rapidly. A systematic technique should be developed to avoid omitting or scanning too rapidly a portion of the reproductive tract. Because the vesicle is moving, it may be found anywhere within the uterine lumen from the tip of a uterine horn to the **cranial** aspect of the cervix (Figure 2-19). It should be emphasized that early detection of an embryonic vesicle requires a high frequency transducer (5 MHz) and a high-quality screen. Frequently, ultrasonographic images of a 10- to 14-day vesicle have a bright echogenic line on the dorsal and ventral poles with respect to the transducer (Figure 2-7). These are not associated with the embryonic disk or other structures of the developing conceptus, but are due to specular reflection. A water-filled balloon (1.5 cm [.59 in] diameter) placed in the uterus will have similar, if not identical, ultrasonographic characteristics.

#### Days 17 to 22

The vesicle is spherical in shape before day 17. The increase in size of vesicle and embryo is presented in Tables 2-1 and 2-2, respectively. Others(6,7) have reported similar data for the equine conceptus (Figure 2-20). The vesicle has a growth plateau between days 17 and 26, then growth resumes at a slightly slower rate (6,7). After day 17, the vesicle is often irregular in shape (Figures 2-10 and 2-11; 7).

**Table 2-1. Size of Vesicle (cm) During Early Gestation**

	Stage of gestation (days)						
	15	20	25	30	35	40	50
Mean size <sup>a</sup>	1.96	2.73	3.22	3.62	4.42	5.94	8.84
± S.D.	.50	.36	.31	.27	.12	.16	.11

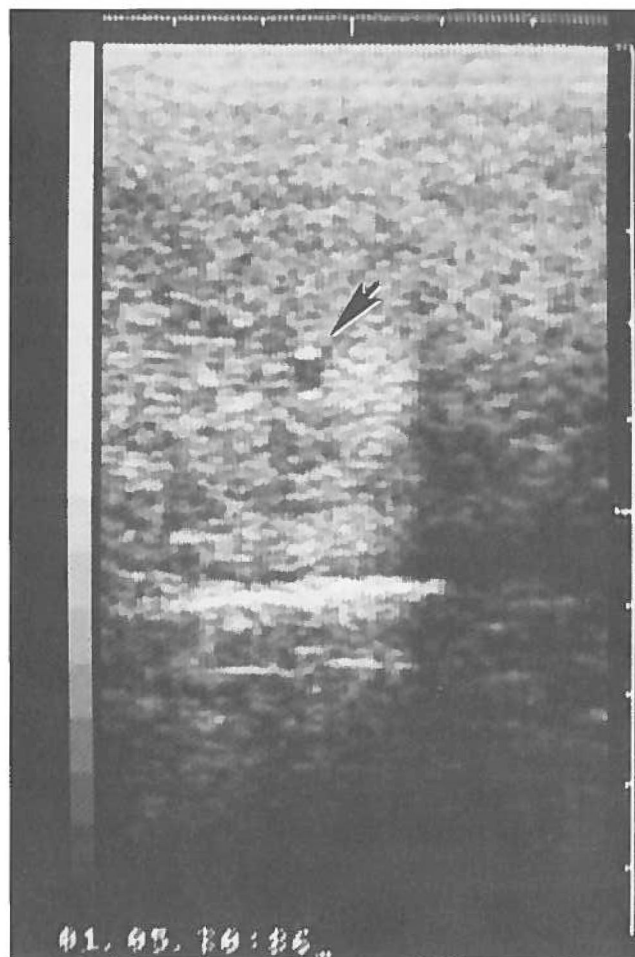
<sup>a</sup> Recorded with a 3 MHz transducer.  
Adapted from(14).

**Table 2-2. Size of Embryo (cm) During Early Gestation**

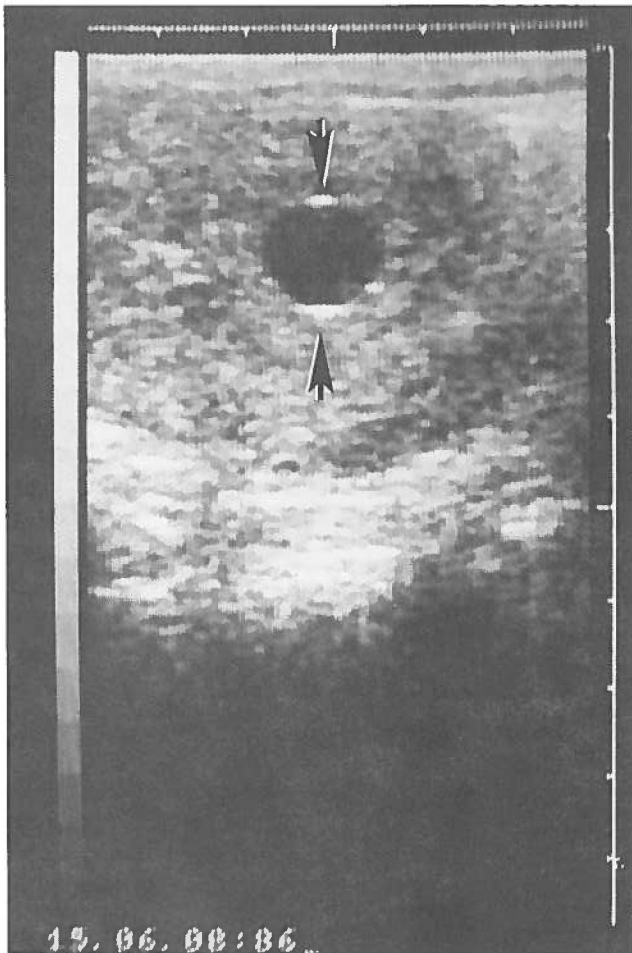
	Stage of gestation (days)				
	25	30	35	40	50
Mean size <sup>a</sup>	1.76	1.95	2.15	2.78	3.49
± S.D.	.59	.51	.46	.36	.28

<sup>a</sup> Recorded with a 3 MHz transducer.  
Adapted from(14).

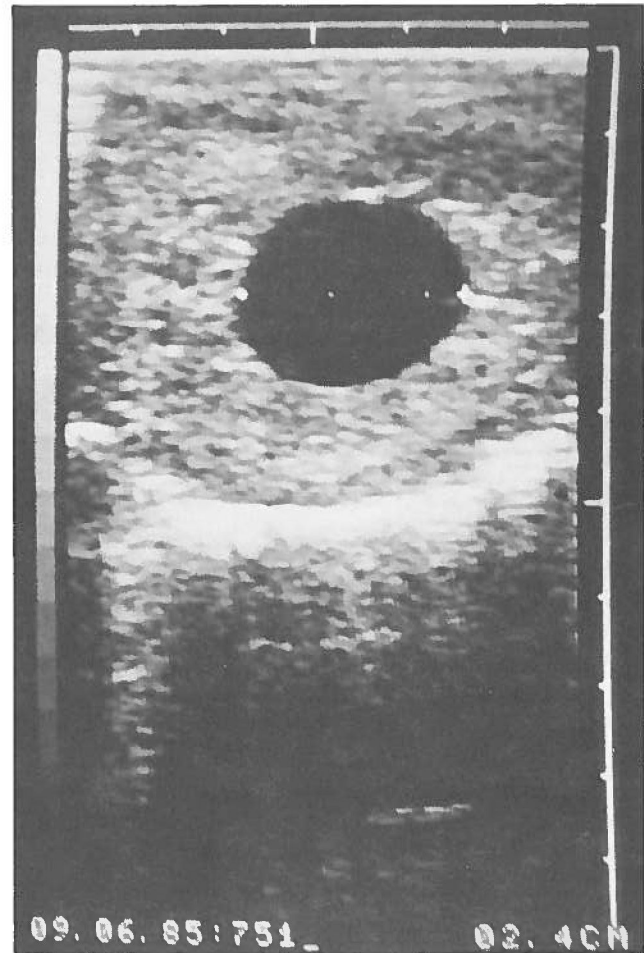
Fixation of the early conceptus on days 16 to 17 apparently is due to increased uterine tone and thickening of the uterine wall as well as rapid growth of the conceptus (5). Increasing uterine tone may explain why the vesicle changes shape as pregnancy advances. Fixation generally occurs in the caudal portion of the uterine horn near the bifurcation (corpus cornual junction). In post-partum mares, the previously gravid horn provides less restriction, thus the conceptus generally fixes in the opposite uterine horn. Fixation occurs with greater frequency in the right horn in maiden and barren mares (4).



**Figure 2-7.** Ultrasonographic image of a 10-day-old pregnancy.



**Figure 2-8.** Ultrasonographic image of a 12-day-old pregnancy. Note the presence of dorsal and ventral specular reflection, which is artifactual (arrow).



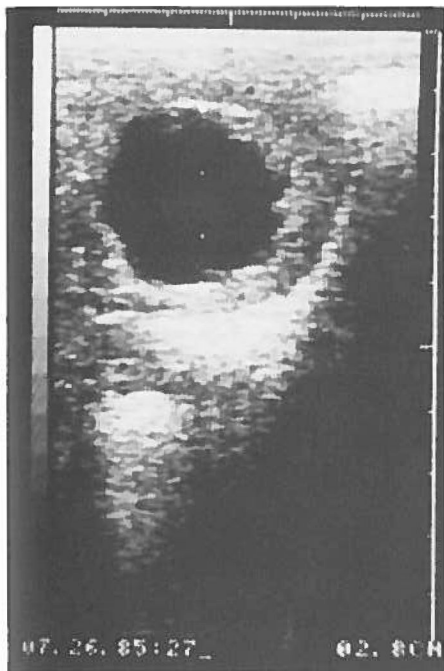**Figure 2-9.** Ultrasonographic image of a 15-day-old pregnancy. The vesicle is still round.

Orientation is defined as rotation of the embryonic vesicle so the embryo proper is on the ventral aspect of the yolk sac. On day 14, the vesicle is highly mobile. Shortly after the end of the mobility phase (days 15 to 17), the dorsal uterine wall begins to enlarge and encroach upon the yolk sac. Encroachment is enhanced by increasing uterine tone. The disproportionate thickening and encroachment of the uterine wall on the vesicle, in addition to the massaging action of uterine contractions, cause the vesicle to rotate so the thickest portion of the yolk sac (embryonic pole) assumes a ventral position (5). Hypertrophy of the uterine wall is especially prominent on each side of the dorsal midline. This probably accounts for the midline location of the apex of the triangularly-shaped vesicle, and the thinness of the uterine wall ventrally. The embryo is first detected ultrasonographically within the vesicle at day 20 to 25, and is most commonly observed in the ventral position (Figure 2-11). The heartbeat is commonly detected about day 22 (1), and is an important indicator of the embryo's well-being.

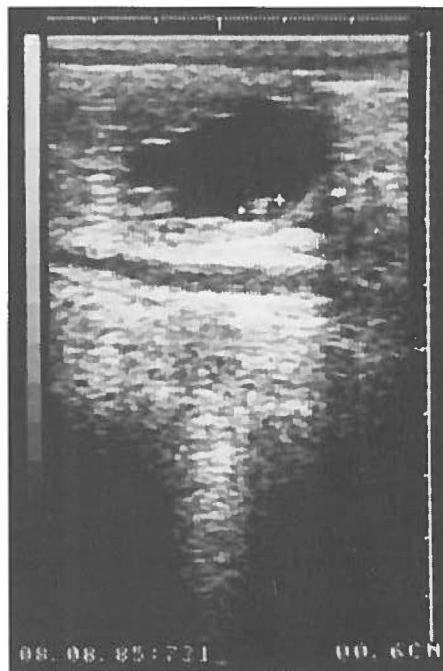
#### **Days 22 to 55**

It is important that the ultrasonographer understands and interprets clinically the growth of the allan-

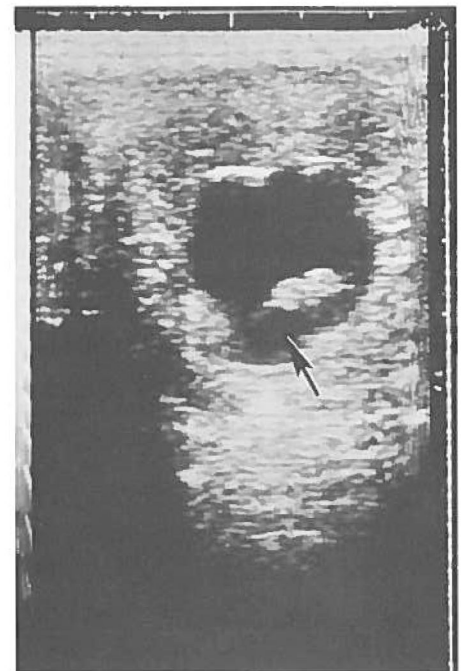
tois, which is initially recognized on day 24 (Figure 2-12) and, concurrent with its expansion, the contraction of the yolk sac. The interplay of growth between these two fluid-filled structures results in the embryo moving from the ventral (day 22; Figure 2-11) to the dorsal (day 40; Figure 2-14) aspect of the vesicle. After day 40 (Figure 2-15), the yolk sac degenerates and the umbilical cord elongates from the dorsal pole, permitting the fetus to gravitate to the ventral floor where it is seen in dorsal recumbency from day 50 onwards (Figure 2-16). Apposition of yolk sac and allantois results in an ultrasonographically visible line normally oriented horizontally (Figure 2-13). On occasion, we have identified this junction in a vertical configuration (Figure 2-17), and believe it has no deleterious effect on continuing pregnancy. Twin vesicle walls, when in contact, generally appear as an ultrasonographically visible, vertically oriented line (Figure 2-18). With knowledge of the approximate stage of gestation and growth characteristics of the conceptus, the clinician can differentiate between the presence of an abnormally oriented singleton (Figure 2-17) or two apposed yolk sacs (twins; Figure 2-18).



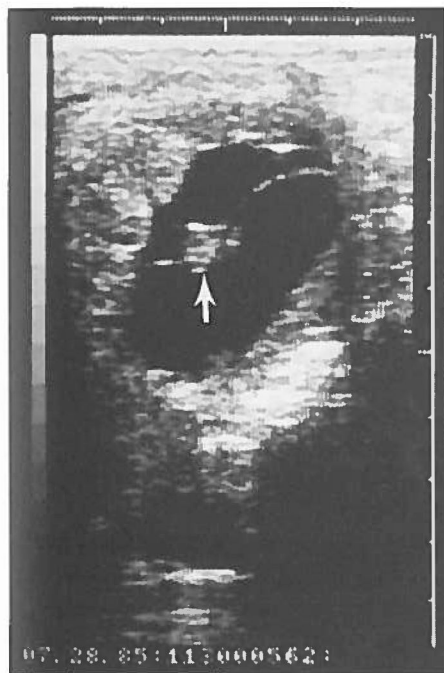**Figure 2-10.** Ultrasonographic image of an 18-day-old pregnancy. The embryonic vesicle has stopped moving and become quite irregular.



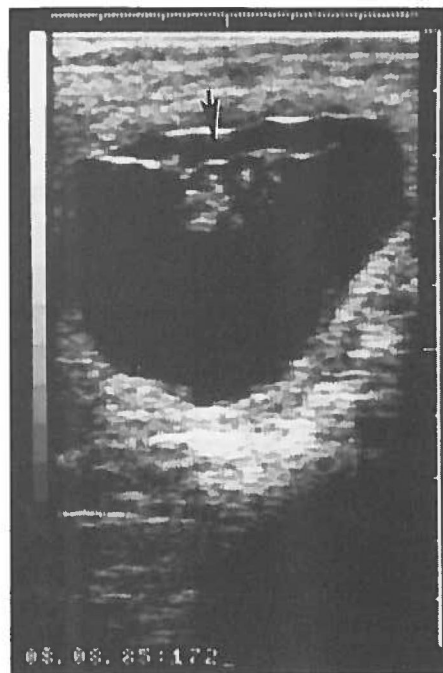**Figure 2-11.** Ultrasonographic image of a 22-day-old embryo (delineated by electronic calipers). The heartbeat is commonly detectable about this time.



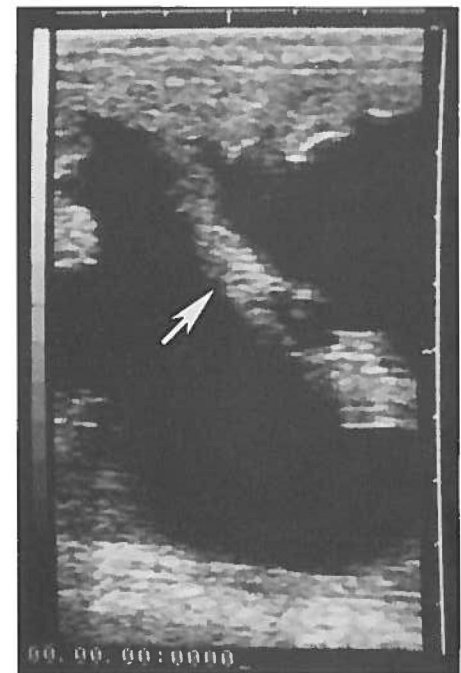
**Figure 2-12.** Ultrasonographic image of a 25-day-old embryo. Note developing allantois (arrow).



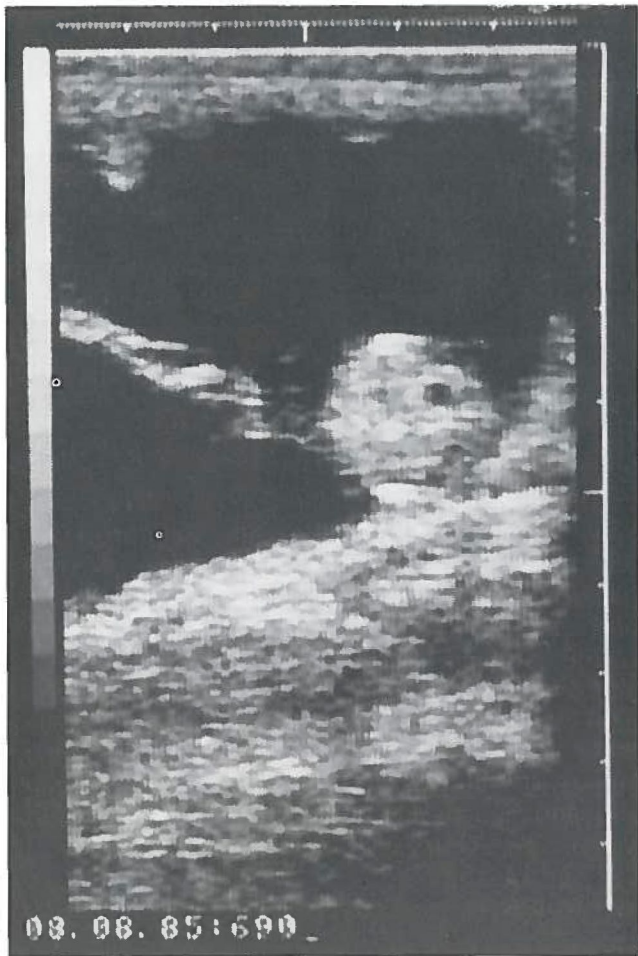**Figure 2-13.** Ultrasonographic image of a 30-day-old pregnancy. Note developing allantois has pushed the embryo (arrow) dorsally, and regression of the yolk sac.



**Figure 2-14.** Ultrasonographic image of a 38-day-old fetus. The yolk sac has almost regressed (arrow).



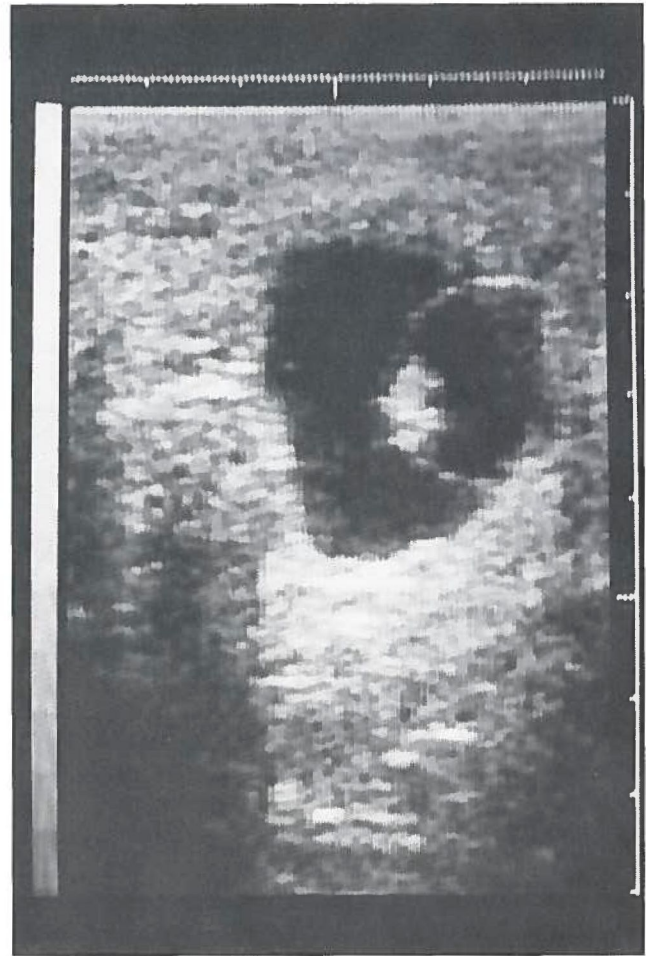**Figure 2-15.** Ultrasonographic image of a 45-day-old fetus. Note developing umbilical cord (arrow).



**Figure 2-16.** Ultrasonographic image of a 55-day-old fetus in dorsal recumbency on the ventral uterine floor.

Developmental abnormalities are more easily detected with ultrasonography than with rectal palpation. On one occasion in our laboratory, ultrasonography was used to detect an abnormally developing fetal monster (Figures 2-21 and 2-22) with excessive fluid in the cranium. Ultrasonography has also been very useful in diagnosis and treatment of twins and in detection of impending EED (Chapter 3).

Obviously, with appropriate equipment, accurate aging of the young fetus is possible by ultrasonographic examination. No reliable method for accurately determining fetal age, late in gestation, has been developed. However, in a study at our laboratory in 1986, fetal eye size (Figures 2-23 and 2-24) determined by ultrasonography was correlated ( $r = 0.92$ ) with fetal age. Presented in Figure 2-25 is a graph that can be used to predict age of the fetus after 100 days of gestation. Measurement of fetal eye size was made with a 5 MHz transducer in mares of known gestational age. Eye size was calculated from the sum of width plus length. Identification of the eye was not difficult due to dorso-pubic positioning of the fetus after day 90.



**Figure 2-17.** Ultrasonographic image of a 26-day-old embryo with apposition of yolk sac and allantois giving the impression of a vertically oriented line.

### **Efficacy of Ultrasonography for Pregnancy Detection in Mares**

Studies were conducted (18) to evaluate the efficacy of ultrasonography for detection of pregnancy. Four hundred and ninety-six nonlactating mares were examined on days 15, 20, 25, 30, 35, 40 and 50 post-ovulation, unless they were not pregnant on consecutive examinations and(or) returned to estrus prior to the next examination date. Based on palpation of the uterus and cervix, the technician made 1 of 3 determinations: open, pregnant or too early for diagnosis. The transducer (3 MHz) was then introduced and moved across the reproductive tract. If a vesicle was located, the image was frozen and electronic calipers were used on the screen to determine the greatest diameter of the vesicle and embryo. Mares were called negative when a vesicle was not located. False negatives were recorded when a mare was determined negative on one scan but positive on a subsequent examination. Mares incorrectly diagnosed as pregnant due to confusion of an embryo with a uterine cyst, a follicle, or other nonechogenic circular structures were considered false positives. A group of 20 nonbred, control



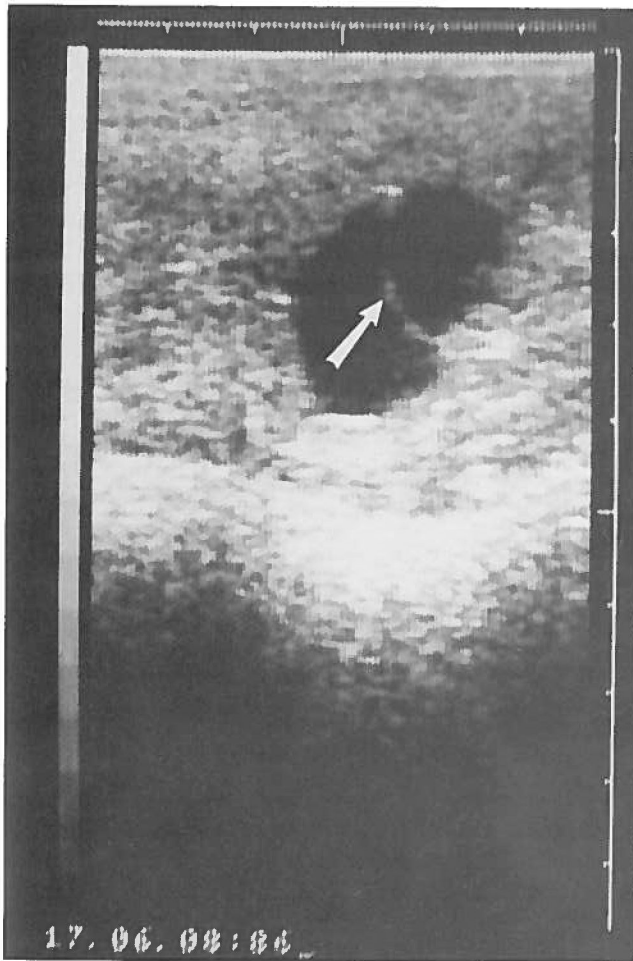


Figure 2-18. Ultrasonographic image of twin 14-day-old conceptuses in apposition. Note vertically oriented line (arrow).

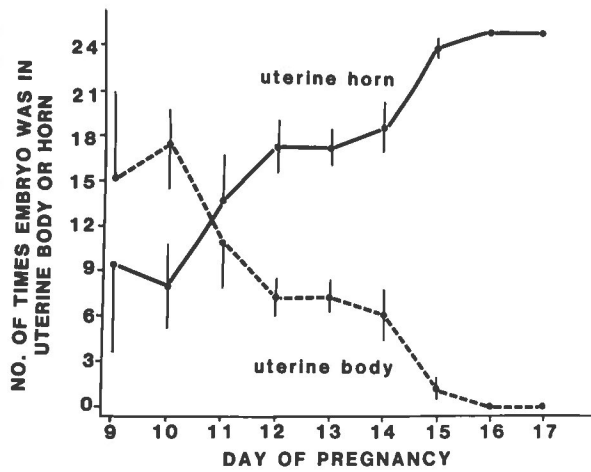


Figure 2-19. Position of vesicle in the uterus in relation to gestation. Adapted from (8).

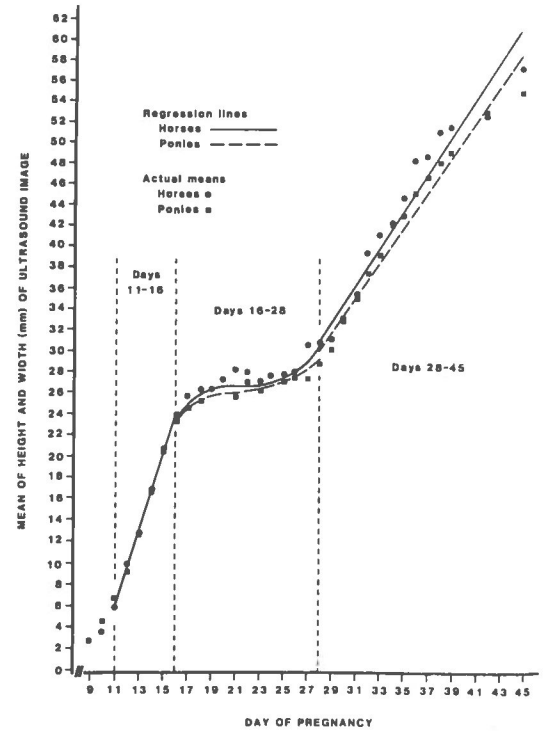


Figure 2-20. Growth characteristics of the conceptus. Adapted from (8).

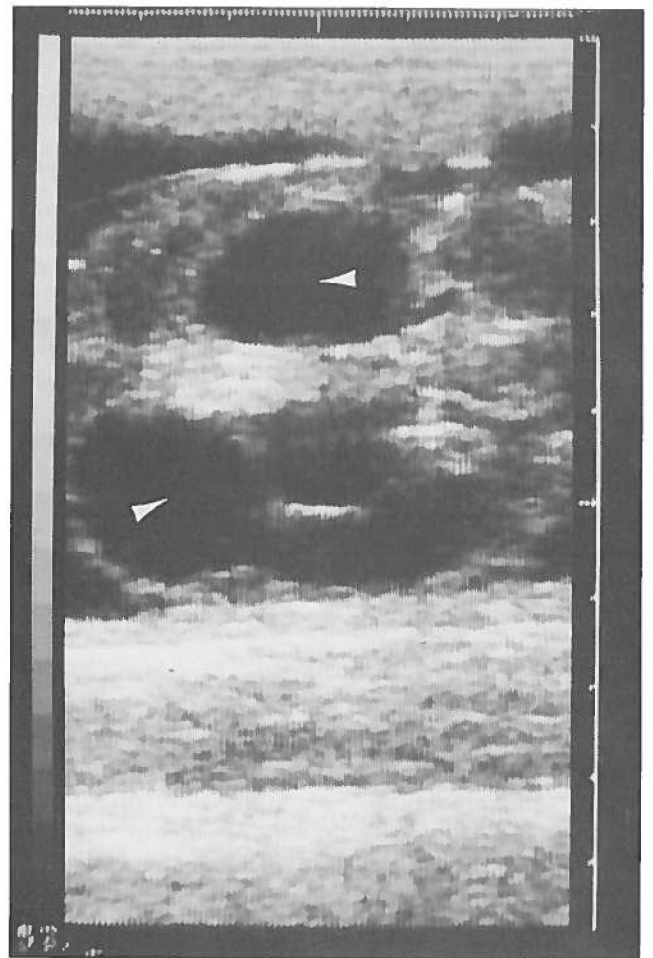
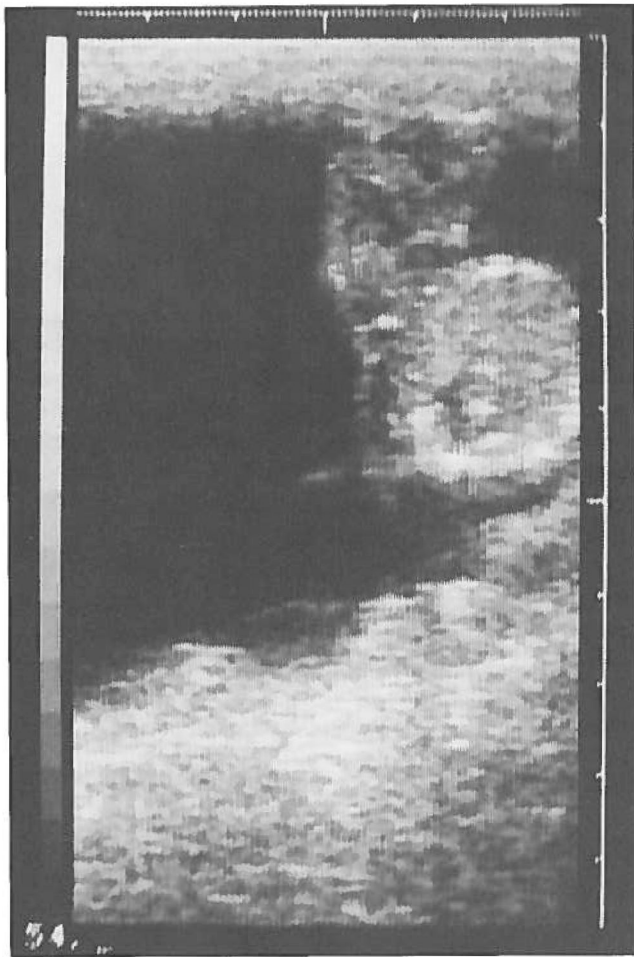
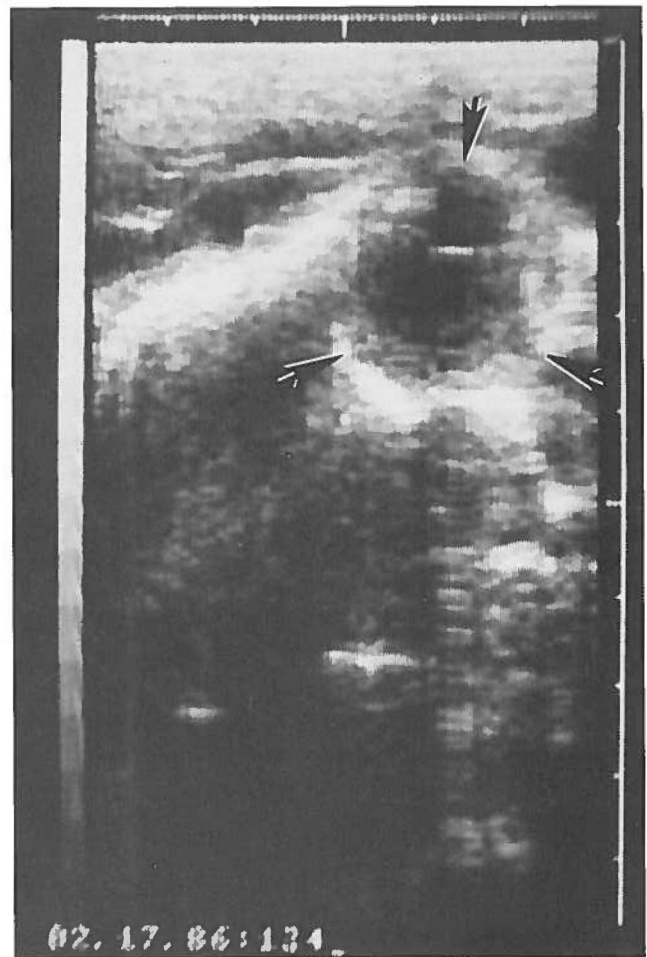


Figure 2-21. Ultrasonographic image of an abnormally developing fetal monster, day 65 post-ovulation. Note fluid accumulation within the head region (arrows).



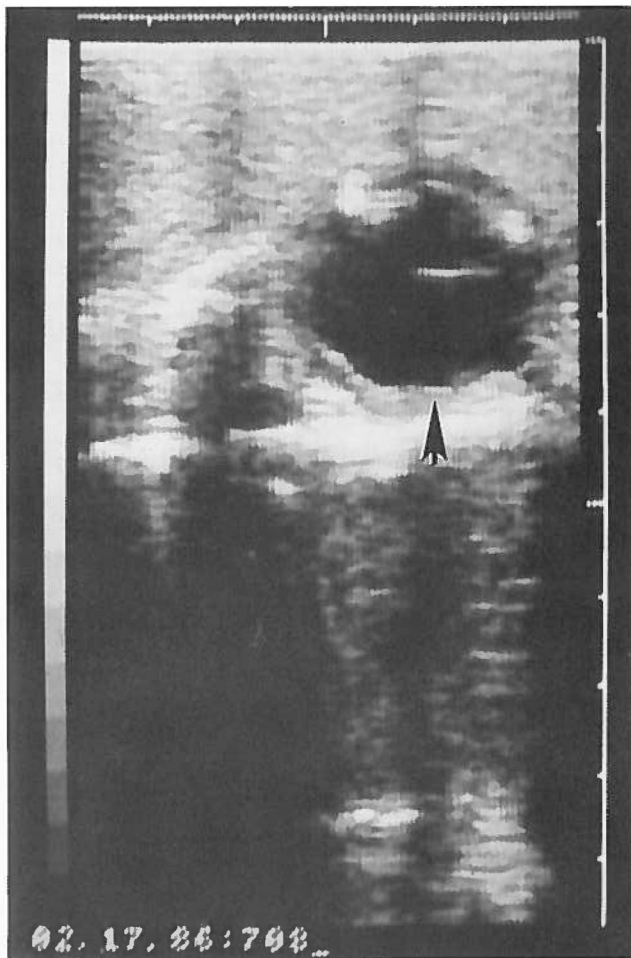
**Figure 2-22.** Ultrasonographic image of a fetus from the same mare as in Figure 2-21 at the same age of gestation. This embryo is believed to be developing normally.

mares was included for examination without the technician being aware of their breeding status. Two technicians (1 and 2) experienced in both rectal palpation and ultrasonography collected data during 1982 and 1983. Two additional technicians (3 and 4), skilled in rectal palpation but not ultrasonography, assisted in collecting data during 1983. Presented in Table 2-3 is the number of mares diagnosed pregnant in 1982, and the accuracy of ultrasonography for detection of pregnancy. The number of mares available for scanning decreased from 15 to 50 days due to mares returning to estrus and(or) early embryonic losses. Accuracy ranged from 97.4 to 100%, and was similar ( $P > 0.05$ ) at all stages of gestation (15 to 50 days). In contrast, the accuracy of rectal palpation for pregnancy detection at 15 days was only 30% and 60%, respectively, for technicians 1 and 2. By day 20, accuracy of ultrasonography and rectal palpation for pregnancy detection was similar ( $P > 0.05$ ; 99.3 and 95.0%, respectively). However, data were biased in that three categories were used for data obtained by rectal examination (pregnant, open and too early for diagnosis), whereas mares were determined either pregnant or open with ultrasonography. The incidence of false negatives as determined

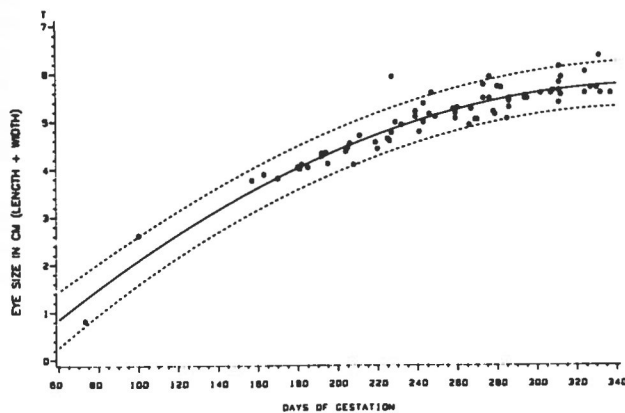


**Figure 2-23.** Ultrasonographic measurement of fetal eye size to estimate fetal age. Note characteristics of the eye from a 180-day developing fetus (arrow).

by ultrasonography was low (ranging from 0 to 2.6%) on days 15 to 50 (Table 2-4). This was probably due to excessive straining by the mare or scanning too rapidly. On occasion, an embryo was found very close to the anterior cervix and it should be emphasized that this area should be scanned carefully. No false positives were recorded in 1982. During 1983, mares were scanned either on the same days as in the 1982 study (Group A) or on days 15, 25, 35 and 50 (Group B). Results are presented in Table 2-5. The accuracy with ultrasonography appeared similar for both years, although direct statistical comparisons probably would not have been valid. Of eight false negatives recorded in 1983, seven were attributed to technicians 3 and 4. Consequently, it appeared that knowledge of ultrasonographic technology as well as skill in rectal palpation were needed for accurate diagnosis. The accuracy of pregnancy detection at 15 days, reported in this study, using a 3.0 MHz, real-time scanner was extremely high and comparable to previous reports (13,17).



**Figure 2-24.** Ultrasonographic measurement of fetal eye size to estimate fetal age. Note characteristics of the eye from a 230-day developing fetus (arrows).



**Figure 2-25.** The relationship between day of gestation and size of fetal eye (length + width in cm with 95% confidence intervals for measurements;  $r = 0.92$ ).

**Table 2-3. Efficacy of Real-Time Ultrasonography for Detection of Pregnancy (1982)**

	Stage of gestation (days)						
	15	20	25	30	35	40	50
No. pregnant mares	167	159	158	151	143	138	132
Diagnosed pregnant:							
No.	165	158	154	150	142	138	132
%	98.7	99.3	97.4	99.3	99.3	100	100

Adapted from(14).

**Table 2-4. Incidence of False Negatives When Diagnosing Pregnancy by Ultrasonographic Scan (1982)**

	Stage of gestation (days)						
	15	20	25	30	35	40	50
No. pregnant mares	167	159	158	151	143	138	132
False negatives:							
No.	2	1	4	1	1	0	0
%	1.3	.7	2.6	.7	.7	0	0

Adapted from(14).

**Table 2-5. Efficacy of Real-Time Ultrasonography for Detection of Pregnancy (1983)**

	Stage of gestation (days)						
	15	20	25	30	35	40	50
No. pregnant mares	141	74 <sup>a</sup>	133	69 <sup>a</sup>	124	65 <sup>a</sup>	121
Diagnosed pregnant:							
No.	138	73	130	70 <sup>b</sup>	124	65	121
%	97.8	98.6	97.7	100	100	100	100

<sup>a</sup> Mares in Group B (65) were not examined on days 20, 30 and 40.

<sup>b</sup> Three false positives.

Adapted from(14).

### Safety of Ultrasonography for Pregnancy Detection in Mares

In humans, no deleterious effects of ultrasonography have been reported (16). A study was performed in our laboratory(18) to determine whether frequent manipulation with the transducer within the mare's rectum or sound waves at a frequency of 3 MHz were detrimental to continuing pregnancy.

Ninety mares were assigned to one of three groups: a) palpated only, b) palpated and scanned with the ultrasonographic machine off, and c) palpated and scanned with the ultrasonographic machine on. All mares were inseminated for one cycle and examined on days 15, 20, 25, 30, 35, 40 and 50 post-ovulation, unless they returned to estrus or were determined negative on three consecutive examinations. Manipulation with the transducer or sound waves produced by the machine did not alter pregnancy rates when compared to mares that were palpated only. First-cycle pregnancy rates were 57, 53 and 67% for mares in groups a, b and c, respectively. These first-cycle pregnancy rates were comparable to those previously

reported from our laboratory (14). Although it is unlikely that practitioners will ultrasonographically examine a mare as often as in this study, particularly during early gestation, this procedure apparently can be performed frequently without fear of detrimental effects on continuing pregnancy.

### REFERENCES

1. Allen, W.E. and P.J. Goddard. 1984. Serial investigations of early pregnancy in pony mares using realtime ultrasound scanning. *Equine Vet. J.* 16:509-514.
2. Austin, C.R. and R. V. Short. 1973. Eds. *Fertilization. Reproduction in mammals. Book 1. Germ cells and fertilization.* Cambridge University Press, London, England.
3. Gidley-Baird, A.A. and C. O'Neil. 1982. Early pregnancy detection in the mare. *Equine Vet. Data* 3:42.
4. Ginther, O.J. 1983. Mobility of the early equine conceptus. *Theriogenology* 19:603-611.
5. Ginther, O.J. 1983. Fixation and orientation of the early equine conceptus. *Theriogenology* 19:613-623.
6. Ginther, O.J. 1984. Ultrasonic evaluation of the reproductive tract of the mare: the single embryo. *J. Equine Vet. Sci.* 4:75-81.
7. Ginther, O.J. 1984. Ultrasonic anatomy and pathology of the reproductive tract. *Proc. Equine Ultrasound Short Course. Colorado State Univ.* pp.16-25.
8. Ginther, O.J. 1986. Ultrasonographic imaging and reproductive events in the mare. *Equiservices, Cross Plains, WI.*
9. Hershman, L. and R. H. Douglas. 1979. The critical period for the maternal recognition of pregnancy in pony mares. *J. Reprod. Fert. Suppl.* 27:395-401.
10. McDowell, K.J., D. C. Sharp, L. S. Peck and L. L. Cheves. 1985. Effect of restricted conceptus mobility on maternal recognition of pregnancy in mares. *Equine Vet. J. Suppl.* 3:23-24.
11. McKinnon, A.O. and E. L. Squires. 1988. Morphologic assessment of the equine embryo. *J.A.V.M.A.* 192:401-406.
12. Oguri, N. and Y. Tsutsumi. 1982. Non-surgical egg transfer in mares. *J. Reprod. Fert.* 41:313-320.
13. Palmer, E. and M. Driancourt. 1980. Use of ultrasonic echography in equine gynecology. *Theriogenology* 13:203-216.
14. Pickett, B.W., E. L. Squires and A. O. McKinnon. 1987. Procedures for collection, evaluation and utilization of stallion semen for artificial insemination. *Colorado State Univ. Anim. Reprod. Lab. Bull. No. 03.*
15. Rolfe, B.E. 1982. Detection of fetal wastage. *Fertil. Steril.* 37:655-660.
16. Sikov, M.R. and B. P. Hildebrand. 1979. Advances in the study of birth defects: Teratological Testing. In: Vol II, Ed. T. V. N. Persaud. University Park Press, Baltimore, MD.
17. Simpson, D.J., R. E. S. Greenwood, S. W. Ricketts, P. D. Rosedale, M. Sanderson and W. R. Allen. 1982. Use of ultrasound echography for early diagnosis of single and twin pregnancy in the mare. *J. Reprod. Fert. Suppl.* 32:431-439.
18. Squires, E.L., J. L. Voss, M. D. Villahoz and R. K. Shideler. 1983. Use of ultrasound in broodmare reproduction. *Proc. 29th Ann. Conv. A.A.E.P.* pp. 27-43.
19. van Niekerk, C.H. and W. H. Gerneke. 1966. Persistence and parthenogenetic cleavage of tubal ova in the mare. *Onderstepoort J. Vet. Res.* 31:195-232.

## Chapter 3

# MANAGEMENT OF TWINS AND EARLY EMBRYONIC DEATH

### Twinning

Multiple pregnancy (twins) in the mare is undesirable because only approximately 60% of mares with twin embryos deliver live, single foals; while 31% lose both pregnancies (17) and 9% carry both foals to term. In addition, of the 9% of twin foals carried to term, both foals are born dead 64.5% of the time, one foal is born alive 21% of the time and live twins occur 14.5% of the time (11). Twinning is second only to **endometritis** as the leading cause of abortion in mares. Mares carrying twins to term often require assistance at birth, and surviving foals are usually weaker, more susceptible to infection and develop more slowly. When twin foals are born alive, one foal is generally weaker and often dies within 3 to 4 days. Mares that abort twin pregnancies often have a higher incidence of retained fetal membranes, do not recycle, and may be difficult to impregnate during the same or subsequent breeding season (17,18). This results in reduction of reproductive efficiency.

A variety of breeding strategies and post-conception treatments have been developed to reduce or prevent twinning in mares. However, until recently most have been unsuccessful. When the likelihood of twinning is high, breeding may be withheld and the mare recycled with prostaglandins. Treatment such as crushing of one vesicle (32) or abortion with prostaglandins or saline (25,33) have been reported as means of managing twin pregnancies.

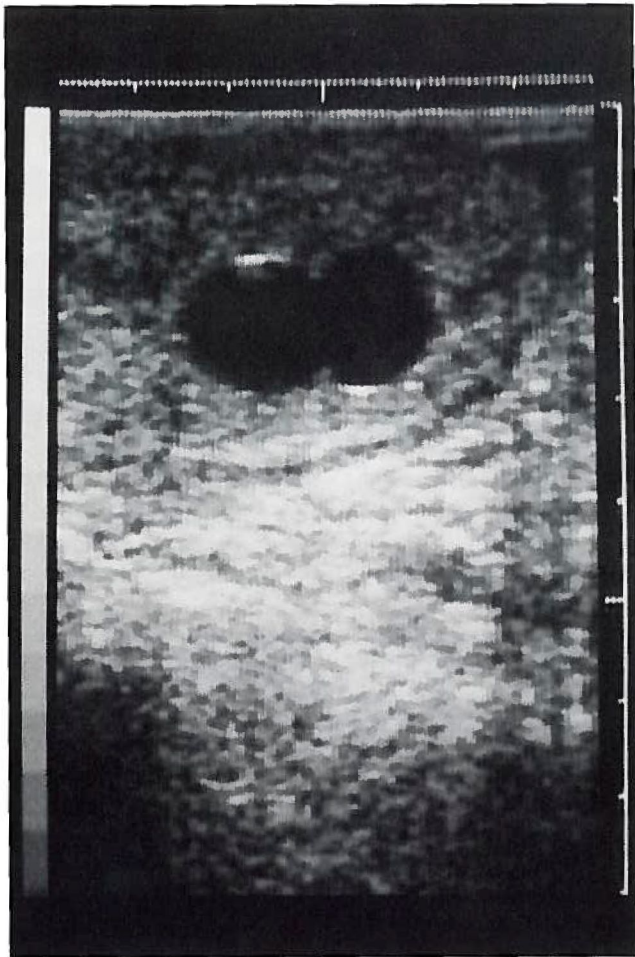
Twins in most species may arise by one of two mechanisms: a) division of a fertilized **ovum**, or b) multiple ovulations resulting in multiple ova (eggs). The possibility of twins occurring from release of a single, fertilized ovum can be discounted in mares since twins are almost always dizygotic, i.e. derived from two ova (23).

Two patterns of double ovulation are recognized: a) synchronous ovulations may occur from either ovary, but are separated by no more than one day; and b) asynchronous ovulations occur from 2 to 10 days apart

during the same estrous period. In the latter case, **progesterone** levels do not rise until after the second ovulation (22). The pattern of ovulation was originally reported to have a dramatic influence on twinning as determined by rectal palpation.

The mare has a natural biological mechanism for elimination of twins (19). This mechanism has been reported to operate less efficiently when twin embryos arise from asynchronous ovulation (13). Further, twin fetuses were rare in association with synchronous ovulation (18). However from results of more recent research, using ultrasonography for pregnancy detection, twins were as likely to occur from synchronous as from asynchronous ovulation (14). Recovery of twin embryos from the uterus 6 to 7 days post-ovulation was not different between synchronous and asynchronous ovulation. In addition, transfer of these embryos into separate recipients usually resulted in two pregnancies with survival rates similar to normal, single embryo transfers (39,40). Therefore, it appears that the embryo reduction mechanism does not become effective until after the embryo enters the uterus, and most commonly is coincident with cessation of the mobility phase (day 16-17; 15).

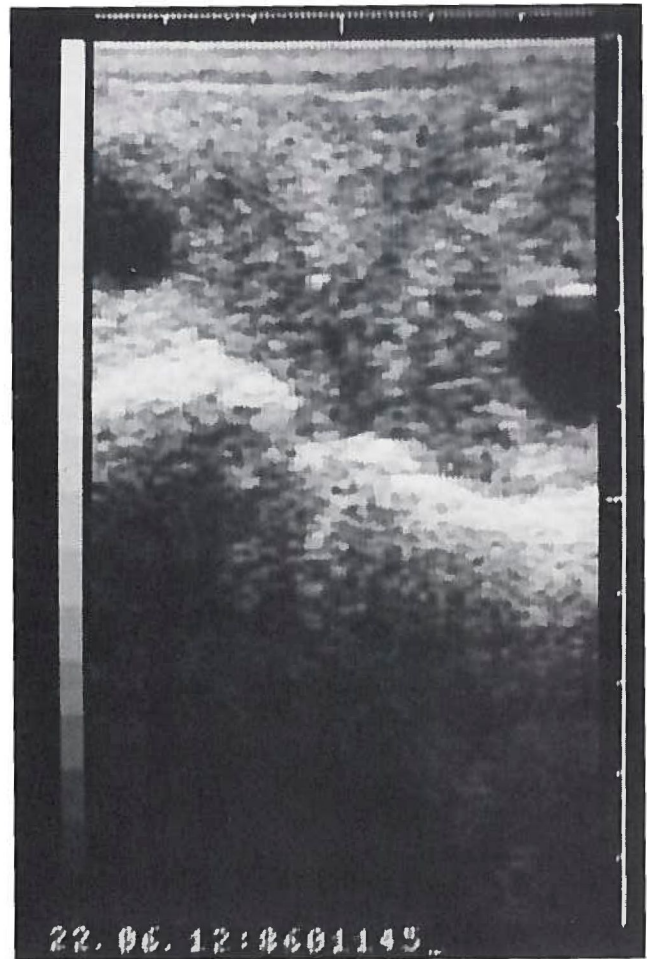
A study was conducted in our laboratory (41), over a 2-year period, to evaluate the outcome of twin pregnancies. A total of 496 nonlactating mares were scanned with a 3 MHz real-time ultrasonographic machine on days 15, 20, 25, 30, 35, 40 and 50 post-ovulation. Mares were of light-horse type, mostly Quarter Horses. Of the 307 mares that became pregnant, 15 twin pregnancies were detected by ultrasonographic scanning. This percentage of twin pregnancies (5.5%) is comparable to that reported for Quarter Horse mares (11,18). One mare that received prostaglandin was eliminated from the study. Fourteen mares carrying twin pregnancies received no treatment prior to day 50 of gestation. Twelve of the mares (85.7%) eliminated one of the pregnancies prior to day 50. One mare underwent loss



**Figure 3-1.** Twelve-day embryonic vesicles prior to separation.

of both embryos between days 15 and 20. Thus, nonintervention resulted in 85.7% of the mares adjusting to a single pregnancy by day 50. This natural, biologic, embryo-reduction mechanism appears to be equally efficient, and in some cases more efficient, than treatments that have been suggested for elimination of one or more twins. More embryonic reductions occurred between days 25 to 30 and 30 to 35 (four in each time period) than between days 15 to 20, 20 to 25, 35 to 40 or 40 to 50 (one in each time period). Unfortunately, number of mares at each time period was too small for meaningful statistical comparisons. Loss of pregnancy could be predicted, in the majority of cases, by measuring size of the vesicle and(or) embryo between time periods. Generally, one conceptus continued to grow, whereas the other vesicle and(or) embryo failed to grow or actually decreased in size between measurement periods.

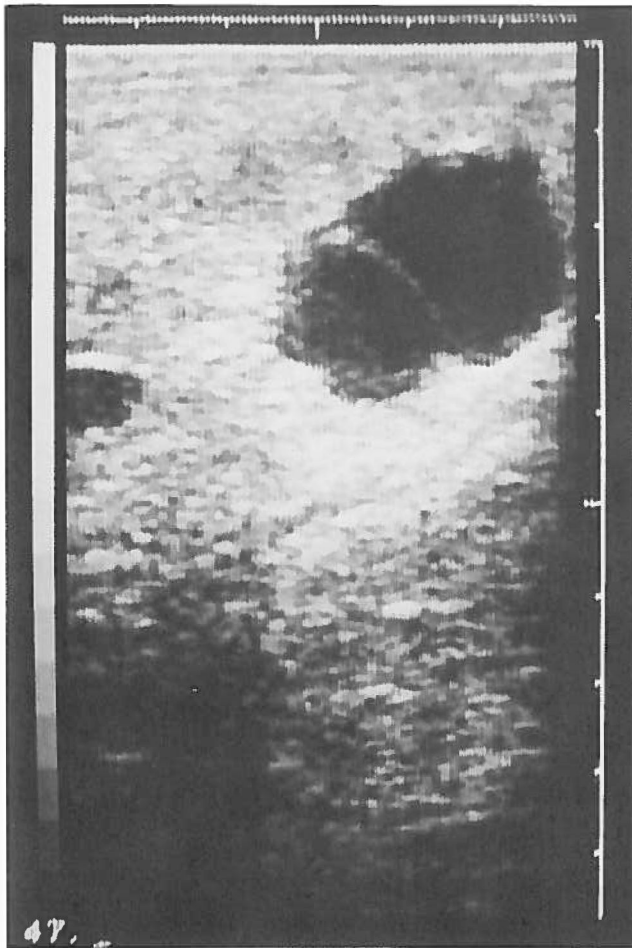The exact mechanism for elimination of one of the embryonic vesicles has not been elucidated, but we believe its success is largely related to how the twin vesicles become fixed in the uterus. Twin vesicles fixed together at one corpus cornual junction approximately 70% of the time (14). When this occurred, successful reduction to a single pregnancy was very com-



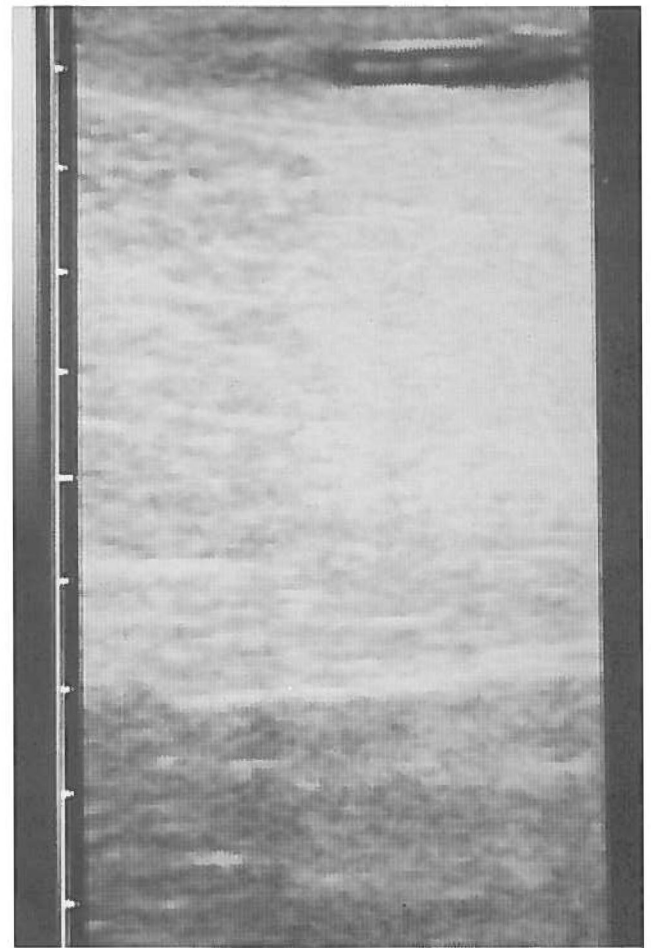
**Figure 3-2.** Separation of the vesicles in Figure 3-1 prior to crushing.

mon. It is possible that embryonic reduction was facilitated by competition for available nutrients. When twin pregnancies fixed at opposite corpus cornual junctions, embryonic reduction was much less frequent (15).

Manual crushing of one twin vesicle between 12 and 30 days of pregnancy resulted in an extremely high (96%) rate of single embryonic reduction (31). Frequent scanning is necessary to identify good separation of the vesicles (Figures 3-1 and 3-2). The smaller vesicle should be manipulated into and crushed at the tip of one uterine horn. Occasionally, a distinct popping sensation is recognized when the vesicle is destroyed. After day 16, the vesicles are likely to be fixed at the corpus cornual junction and manual reduction may be more difficult, particularly if both are fixed on the same side (Figure 3-3). Crushing of one vesicle is then performed *in situ* (31). Throughout the 1987 and 1988 breeding seasons at our laboratory, twins have been successfully reduced by manipulation with the transducer. The ability to gently and accurately separate twins and manipulate one into the extremity of a uterine horn is greatly facilitated by monitoring with ultrasonography. The uterine horn is forced against the cranial and lateral margin of the pelvis and pres-



**Figure 3-3.** Two 16-day embryonic vesicles fixed together at one corpus cornual junction.



**Figure 3-4.** Destruction of one twin vesicle with pressure from a transducer.

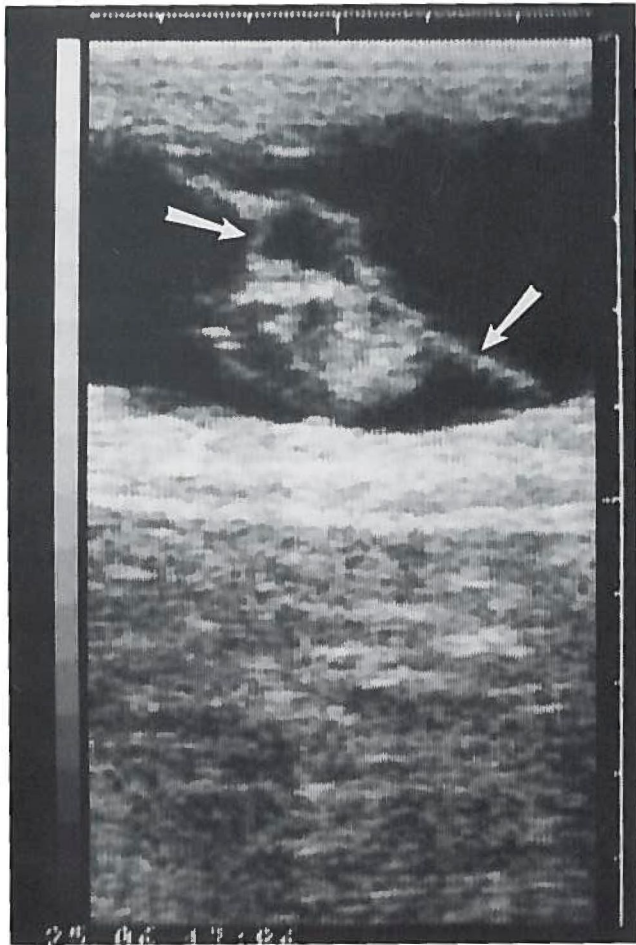
sure increased by forcing the transducer down onto the vesicle (Figure 3-4) until the vesicle is destroyed.

Monitoring with ultrasonography and nonintervention until day 30 is another accepted method of treatment. If a mare has not adjusted to one pregnancy by day 30, prostaglandins can be administered to terminate the pregnancy. Prostaglandins should be given prior to formation of endometrial cups (days 35 to 40). If rebreeding is not desired or practical, induction of abortion can be delayed for as much as 70 to 80 days. When twins are diagnosed after formation of endometrial cups (Figure 3-5), surgical intervention to remove one conceptus has been advocated (30). This technique (30) was most successful when twins became fixed in opposite corpus cornual junctions (8 single foals from 10 twin pregnancies) compared to when twins fixed together (0 foals from 8 twin pregnancies).

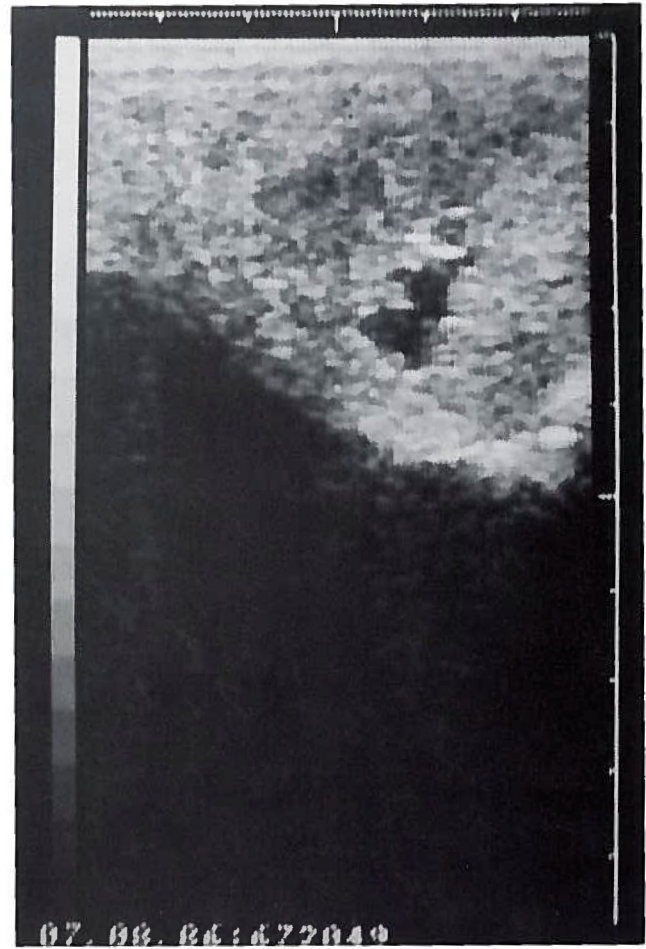
A sophisticated technique involving cardiac puncture of one co-twin and lethal injection of potassium chloride is currently being used in Kentucky (34). This procedure is performed with either a 3 or 5 MHz sector transducer with a biopsy-needle guide attached. After tranquilization of the mare, the fetus is identified by transcutaneous ultrasonography. After confirming that the mare has twin pregnancies, an attempt is made to

identify a discrepancy in size between the vesicles. If there is a size difference, fetal reduction may have already been initiated by the mare. When it becomes possible to determine fetal sex, this may become the criterion for fetal destruction. A 6-inch, 18-gauge needle is inserted into the heart of the chosen fetus, while monitoring directly with ultrasonography, and potassium chloride is injected until cessation of heart-beat. This procedure has been performed in over 30 mares, with the earliest pregnancy being 54 days and the latest 168 days. However, twin pregnancies between 70 and 110 days of gestation are preferred (34). Approximately 50% of the cases treated have resulted in mummification of one fetus, while the other proceeded to term. Unfortunately, the other sequel is death and abortion of both fetuses within 30 days of the procedure. It was difficult to determine if these abortions were the natural tendency of mares to eliminate twins (34), or a result of intrauterine invasion. No adverse effects on health of mares have been recorded. However, this is not a stage of gestation when a large percentage of abortions are expected from mares carrying twin pregnancies.

It is possible that methods will be developed that will allow one fetus to be carried successfully to term des-



**Figure 3-5.** Twin 45-day pregnancies. Note presence of two umbilical cords (arrows).



**Figure 3-6.** Small amount of fluid remaining at the corpus cornual junction after expulsion of the fetus.

pite twin pregnancy determined late in gestation. On three occasions, when premature lactation began at approximately 8 mo of gestation, and supplemental progesterone was initiated and continued up to 2 wks prior to expected delivery, a live foal was delivered concurrent with a mummified fetus (35). Although the live foals were small, each nursed and continued to develop normally. We have observed similar occurrences (37). However, further research is needed prior to recommendation of widespread supplementation of progesterone to mares with twin pregnancies.

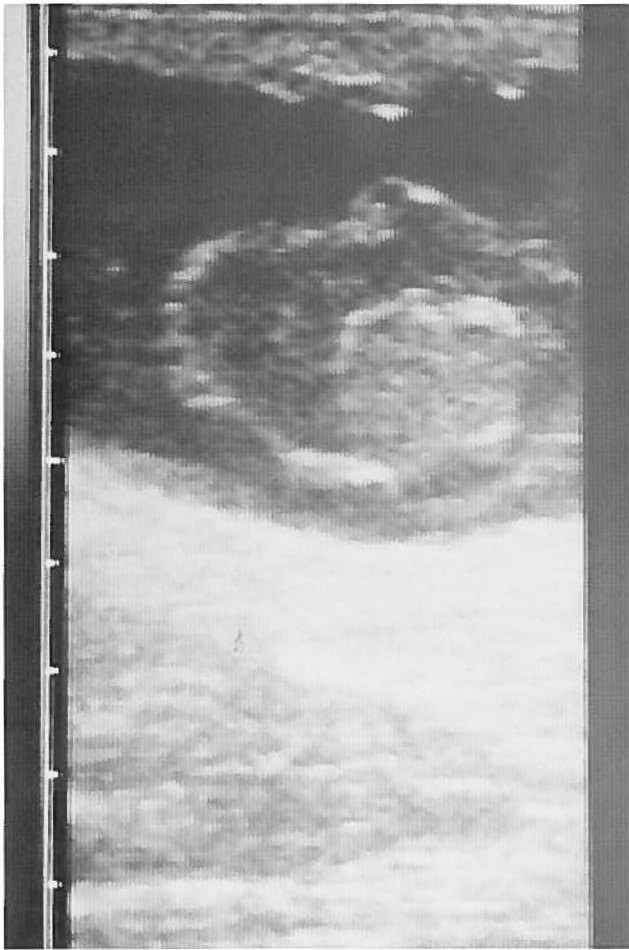### Early Embryonic Death

Early embryonic death results in low reproductive performance of mares (5). Notifying the client that a valuable mare has undergone embryonic loss is a distressing experience for a breeding manager or veterinarian. Clients enthusiastically support use of ultrasonography for early pregnancy detection. However, not all pregnancies continue to survive, even in normal mares. Improvement in ultrasonographic equipment has permitted investigation of early embryonic losses between days 10 and 20 of gestation (46). This technique, combined with embryo recovery, permits inves-

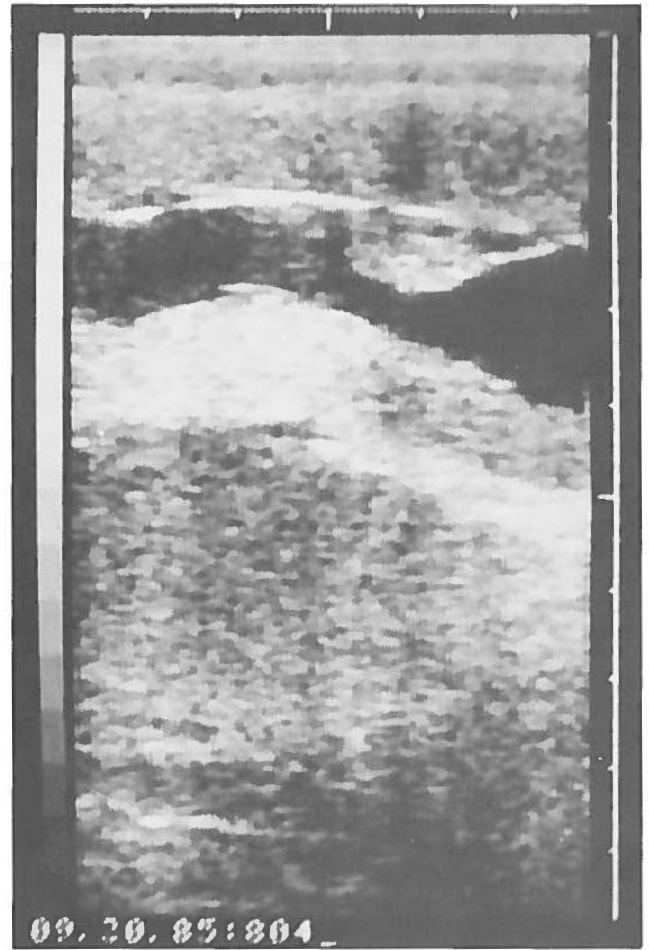
tigation of embryonic losses between day 6, which is the first time an embryo can be recovered from the uterus, and day 10, which is the first time the vesicle can be consistently detected by ultrasonography. The incidence of EED prior to day 6 is unknown. However, it was suggested that a major proportion of EED in infertile mares occurred in the oviduct (4). The incidence of EED has been reported to be between 5 and 30% of established pregnancies (8,24,36,38). In recent studies utilizing ultrasonography, it appeared that EED occurred in mares much earlier than previously reported (16,46). Various causes and factors responsible for EED in mares, apart from presence of twins, have been suggested; which included nutrition (6,44,45), plant estrogens and photoperiod (42), seminal treatments (28), lactational stress and foal-heat breedings (27), genital infections (8,21,27,36), chromosomal abnormalities (7), hormonal deficiencies (44), anabolic steroids (46), stress (43,44), failure of maternal recognition and deficiency of pregnant mare serum gonadotropin (PMSG) production (1,2).

Migration of the conceptus was originally believed to be a contributing factor in EED (29). However, it is now known to be a normal characteristic of the horse conceptus (12). Lactating mares and mares bred during





**Figure 3-7.** Early embryonic death. Note disruption of placental membranes, and increased echogenicity of fetal fluid.



**Figure 3-8.** Early embryonic death. The embryo is being expelled through the cervix.

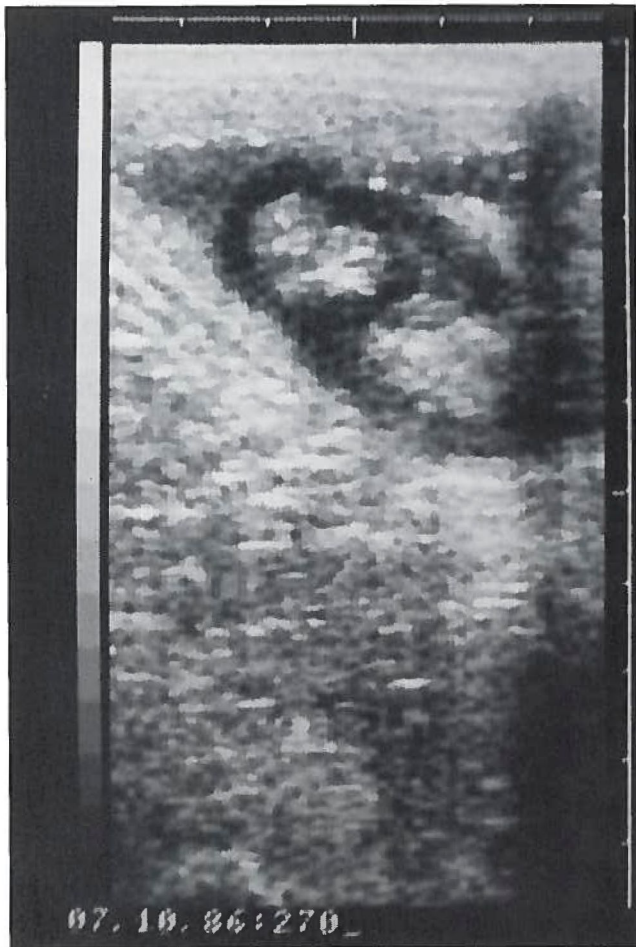foal heat have been reported to have a higher incidence of EED than nonlactating mares (10,26,27). However, in a survey of 2,562 pregnancies in lactating and nonlactating mares, the incidence of EED was similar(3).

Prior to the advent of ultrasonography, recognition and timing of EED was difficult. From data collected at our laboratory (46) over two breeding seasons involving 356 mares diagnosed pregnant utilizing ultrasonography, the overall incidence of EED through day 50 post-ovulation was 17.3%. The majority (77.1%) of EED occurred prior to day 35 post-ovulation. During the period 15 to 35 days post-ovulation, a greater ( $P < 0.05$ ) incidence of EED occurred between days 15 to 20 (26.2%) and 30 to 35 (29.5%) post-ovulation compared to other time periods. Maternal recognition of pregnancy has been reported to occur between 14 and 16 days post-ovulation (20). In the study at our laboratory, 13.3% of mares pregnant at day 15 lost their pregnancy by day 35 (46). It should be noted that formation of endometrial cups occurs on approximately day 35.

The highest incidence of EED (38.9%) recorded in our laboratory has been for mares with previous histories of infertility. These mares had been inseminated for two cycles and failed to conceive, had poor uterine biopsies or previously had clinical signs of endometri-

tis. The high incidence of EED is not surprising, since some of the mares had previously experienced EED or had failed to become pregnant during two cycles. Abnormal conditions of the uterus probably contributed to the higher incidence of EED. The relationship between biopsy grade and pregnancy rates and(or) foaling rates is well-established (24,38). Breeders and veterinarians should be aware of a greater discrepancy between pregnancy rates and foaling rates for mares with a history of reproductive problems compared to normal, healthy mares.

Early embryonic death is diagnosed, in our laboratory, when an embryonic vesicle seen previously is not observed on two consecutive ultrasonographic scans and(or) when only remnants of a vesicle are observed (Figure 3-6). Ultrasonographic criteria for impending EED are an irregular and indented vesicle, fluid in the uterine lumen and vesicular fluid that contains echogenic spots (Figure 3-7). Early embryonic death is suspected, particularly after day 30, when no fetal heart-beat is observed, there is poor definition of fetal structure, and the largest diameter of the fetal vesicle is two standard deviations smaller than the mean established for that specific day of age, post-ovulation. Vesicles increasing in size more slowly than normal are also



**Figure 3-9.** Early embryonic death. Note resorption of fetal fluids.



**Figure 3-10.** Fetal fluid protruding into the cervix.

characteristic of EED (16). Indications obtained by ultrasonographic scanning (16) of impending loss at later stages include: failure of fixation, an echogenic ring within the vesicle, a mass floating in a collection of fluid and a gradual decrease in volume of placental fluid with disorganization of placental membranes (Figures 3-8 to 3-14).

Ultrasonographic scanning, during early pregnancy, is an extremely useful management tool for pregnancy detection and determination of EED. However, if pregnancy rates are not reported until day 50, the discrepancy between pregnancy and foaling rates decreases.

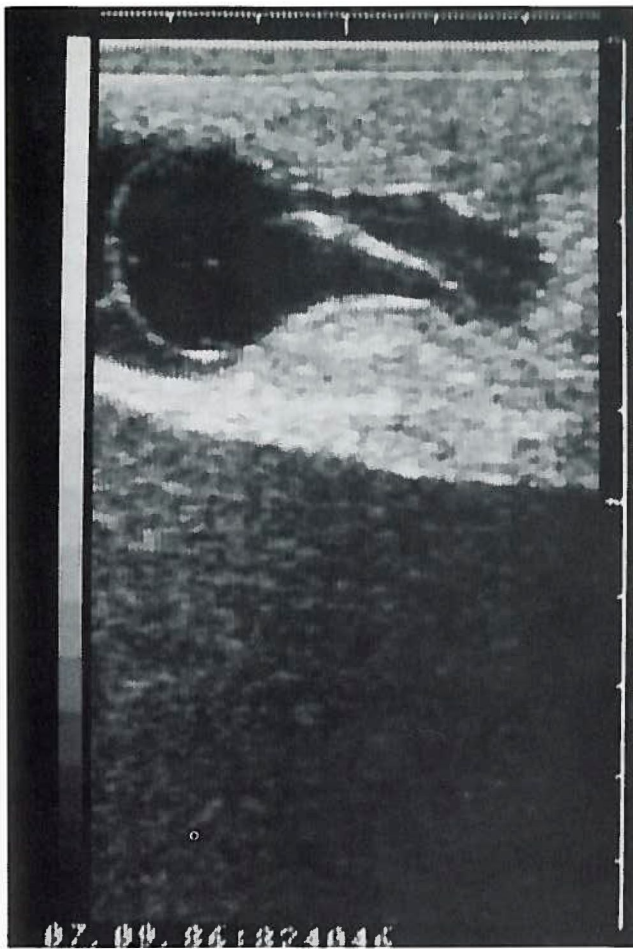
### Prevention and Management of EED

There are few, if any, treatments to consistently decrease incidence of EED, but **artificial insemination** can limit bacterial challenge to a mare's uterus, thus reducing potential losses from endometritis. In addition, any new information on causes and treatment of endometritis should result in increased breeding efficiency. The transfer of embryos from mares with poor uterine-biopsy grades into normal recipient mares is recommended to provide an environment more con-

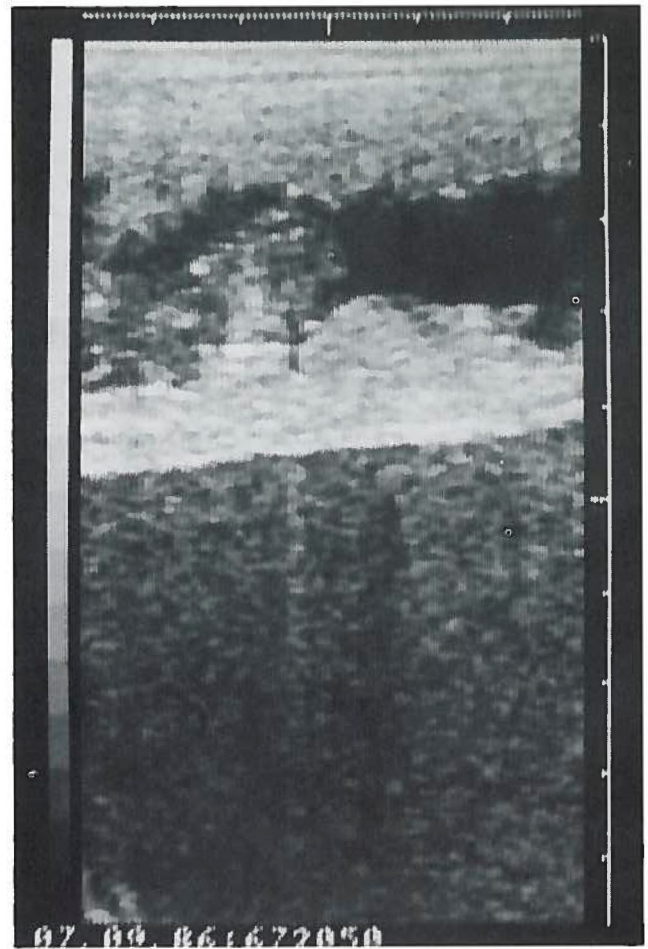
ducive to pregnancy maintenance (38). Unfortunately, recovery of embryos from infertile mares is low. Supplementation with progesterone to habitually aborting mares or mares with primary luteal inadequacy has been advocated (9). However, there is little experimental evidence on the efficacy of this procedure(2). Perhaps the changes most likely to result in a decrease in incidence of EED are improving management factors related to nutrition, environmental temperature, infectious diseases and other stresses.

### REFERENCES

1. Allen, W.R. 1979. Maternal recognition of pregnancy and immunological implications of trophoblast-endometrium interactions in equids. In: Maternal Recognition of Pregnancy, Ciba Foundation Symposium 64, Excerpta Medica, New York, NY.
2. Allen, W.R. 1984. Is your progesterone therapy really necessary? *Equine Vet. J.* 16:496-498.
3. Bain, A.M. 1969. Foetal losses during pregnancy in the Thoroughbred mare: a record of 2,562 pregnancies. *N. Z. Vet. J.* 17:155-158.

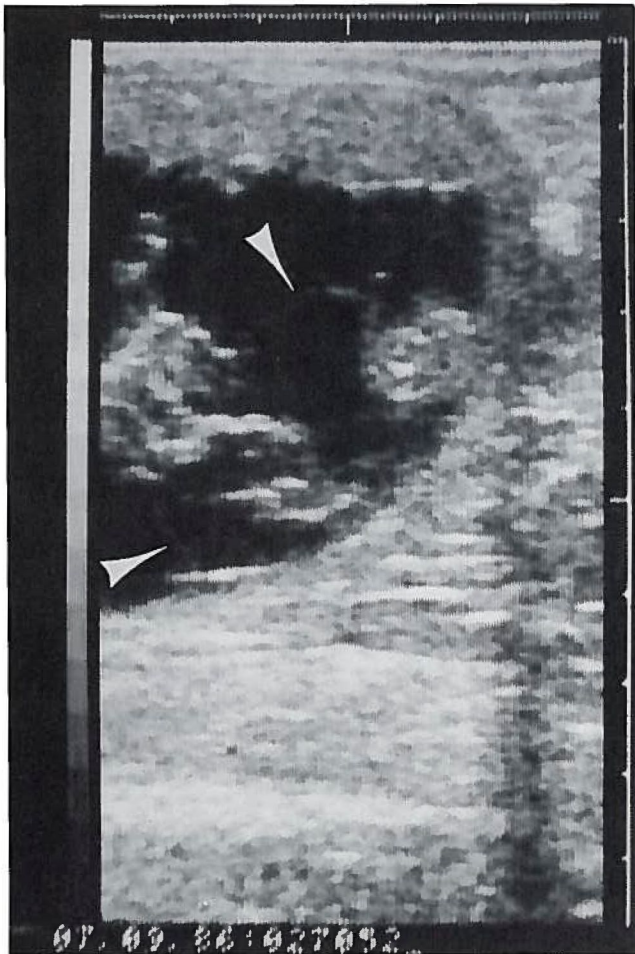


**Figure 3-11.** Apparent increase in size of the amniotic cavity and loss of embryo outline.

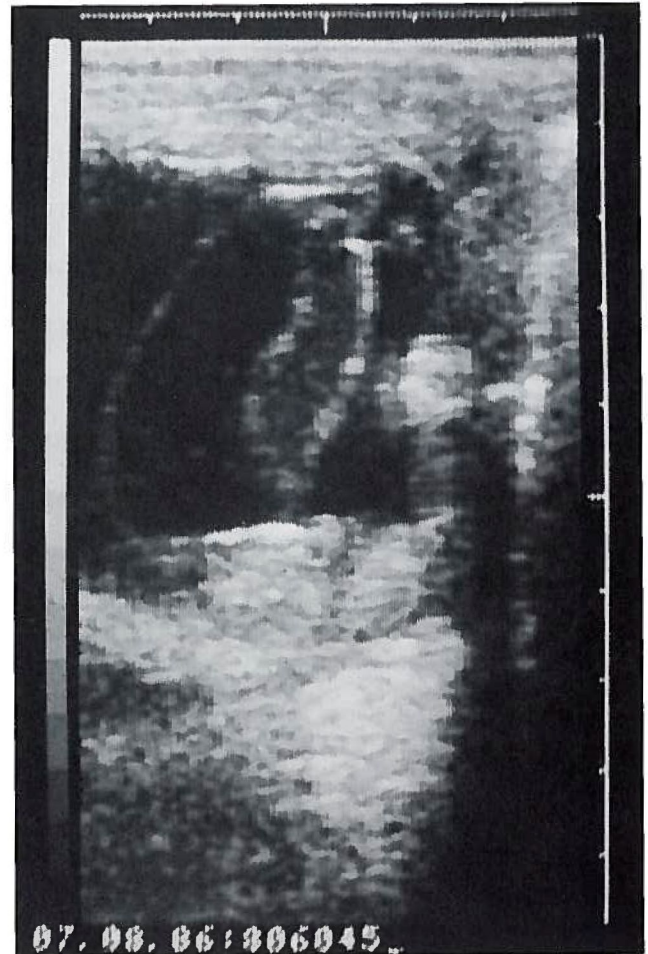

**Figure 3-12.** Decreased fetal fluids. Fetus is in the uterine body instead of at the corpus cornual junction.

4. Ball, B.A., T. V. Little, R. B. Hillman and G. L. Woods. 1986. Pregnancy rates at days 2 and 14 and estimated embryonic loss rates prior to day 14 in normal and subfertile mares. *Theriogenology* 26:611-619.
5. Ball, B.A. and G. L. Woods. 1987. Embryonic loss and early pregnancy loss in the mare. *Compend. Cont. Educ. Pract. Vet.* 9:459-471.
6. Belonje, P.C. and C. H. van Niekerk. 1975. A review of the influence of nutrition upon the oestrous cycle and early pregnancy in the mare. *J. Reprod. Fert. Suppl.* 23:167-169.
7. Bishop, M.W.H. 1964. Paternal contribution to embryonic death. *J. Reprod. Fert.* 7:383-396.
8. Day, F.T. 1940. Clinical and experimental observations on reproduction in the mare. *J. Agri. Sci.* 30:244-261.
9. Douglas, R.H., P. J. Burns and L. Hershman. 1985. Physiological and commercial parameters for producing progeny from subfertile mares by embryo transfer. *Equine Vet. J. Suppl.* 3:111-114.
10. Fiolka, V.G., H.-J. Kuller and S. Lender. 1985. Embryonale Mortalität beim Pferd. *Mh. Vet.-Med.* 40:835-838.
11. Ginther, O.J. 1982. Twinning in mares: a review of recent studies. *J. Equine Vet. Sci.* 2:127-135.
12. Ginther, O.J. 1983. Mobility of the early equine conceptus. *Theriogenology* 19:603-611.
13. Ginther, O.J. 1983. Effect of reproductive status on twinning and on side of ovulation and embryo attachment in mares. *Theriogenology* 20:383-395.
14. Ginther, O.J. 1987. Relationships among number of days between multiple ovulations, number of embryos, and type of embryo fixation in mares. *Theriogenology* 7:82-88.
15. Ginther, O.J. 1988. Using a twinning tree for designing equine twin-prevention programs. *J. Equine Vet. Sci.* 8:101-107.
16. Ginther, O.J., D.R. Bergfelt, G. S. Leith and S. T. Scraba. 1985. Embryonic loss in mares: incidence and ultrasonic morphology. *Theriogenology* 24:73-86.
17. Ginther, O.J. and R. H. Douglas. 1982. The outcome of twin pregnancies in mares. *Theriogenology* 18:237-244.
18. Ginther, O.J., R. H. Douglas and J. R. Lawrence. 1982. Twinning in mares: a survey of veterinarians and analyses of theriogenology records. *Theriogenology* 18:333-347.



**Figure 3-13.** Disrupted placental membranes (arrows).



**Figure 3-14.** Apparent increase in size of the amniotic cavity with increased echogenicity of amniotic fluid.

19. Ginther, O.J., R. H. Douglas and G. L. Woods. 1982. A biological embryo-reduction mechanism for the elimination of excess embryos in mares. *Theriogenology* 18:475-485.
20. Hershman, L. and R. H. Douglas. 1979. The critical period for the maternal recognition of pregnancy in pony mares. *J. Reprod. Fert. Suppl.* 27:395-401.
21. Hoppe, R. 1968. The embryonic mortality in the mare. *Proc. 6th Internat. Congr. Anim. Reprod. A.I.* 2:1573-1576.
22. Hughes, J.P., G. H. Stabenfeldt and J. W. Evans. 1972. Clinical and endocrine aspects of the estrous cycle of the mare. *Proc. 18th Ann. Conv. A.A.E.P.* pp.119-151.
23. Jeffcott, L.B. and K. E. Whitwell. 1973. Twinning as a cause of foetal and neonatal loss in the Thoroughbred mare. *J. Comp. Path.* 83:91-106.
24. Kenney, R.M. 1978. Cyclic and pathologic changes of the mare endometrium as detected by biopsy, with a note on early embryonic death. *J.A.V.M.A.* 172:241-262.
25. Kooistra, L.H. and O. J. Ginther. 1976. Termination of pseudopregnancy by administration of prostaglandin  $F_{2a}$  and termination of early pregnancy by administration of prostaglandin  $F_{2a}$  or colchicine or by removal of the embryo in mares. *Am. J. Vet. Res.* 37:35-39.
26. Lieux, P. 1980. Comparative results of breeding on first and second post-foaling heat periods. *Proc. 26th Ann. Conv. A.A.E.P.* pp.129-132.
27. Merkt, H. and A.-R. Gunzel. 1979. A survey of early pregnancy losses in West German Thoroughbred mares. *Equine Vet. J.* 11:256-258.
28. Moberg, R. 1975. The occurrence of early embryonic death in the mare in relation to natural service and artificial insemination with fresh or deep-frozen semen. *J. Reprod. Fert. Suppl.* 23:537-539.
29. Moberg, R. 1976. The possible influence of site of pregnancy compared with site of ovulation on the incidence of early embryonic death in the mare. *Proc. 8th Internat. Congr. Anim. Reprod. A.I.* 4:610-612.

30. Pascoe, D.R. 1988. Personal communication. Oakey Veterinary Clinic. Oakey, Queensland, Australia.
31. Pascoe, D.R., R. R. Pascoe, J. P. Hughes, G. H. Stabenfeldt and H. Kindahl. 1987. Comparison of two techniques and three hormone therapies for management of twin conceptuses by manual embryonic reduction. *J. Reprod. Fert. Suppl.* 35:701-702. (Abstr.).
32. Pascoe, R.R. 1979. A possible new treatment for twin pregnancy in the mare. *Equine Vet. J.* 11:64-65.
33. Pascoe, R.R. 1983. Methods for the treatment of twin pregnancy in the mare. *Equine Vet. J.* 15:40-42.
34. Rantanen, N.W. 1988. Personal communication. P.O. Box 11849, Lexington, KY 40578-1849.
35. Roberts, S.J. and G. Myhre. 1983. A review of twinning in horses and the possible therapeutic value of supplemental progesterone to prevent abortion of equine twin fetuses the latter half of the gestation period. *Cornell Vet.* 73:257-264.
36. Rosedale, P.D. and S.W. Ricketts. 1980. *Equine Stud Farm Medicine*. 2nd ed. Lea & Febiger, Philadelphia, PA.
37. Shideler, R.K. 1987. Prenatal lactation associated with twin pregnancy in the mare: a case report. *J. Equine Vet. Sci.* 7:383-385.
38. Shideler, R.K., A. E. McChesney, J. L. Voss and E. L. Squires. 1982. Relationship of endometrial biopsy and other management factors on fertility of broodmares. *J. Equine Vet. Sci.* 2:5-10.
39. Squires, E.L., R. H. Garcia and O. J. Ginther. 1985. Factors affecting success of equine embryo transfer. *Equine Vet. J. Suppl.* 3:92-95.
40. Squires, E.L., A. O. McKinnon, E. M. Carnevale, R. Morris and T. M. Nett. 1987. Reproductive characteristics of spontaneous single and double ovulating mares and superovulated mares. *J. Reprod. Fert. Suppl.* 35:399-403.
41. Squires, E.L., J. L. Voss, M. D. Villahoz and R. K. Shideler. 1983. Use of ultrasound in broodmare reproduction. *Proc. 29th Ann. Conv. A.A.E.P.* pp.27-43.
42. Swerczek, T.W. 1980. Early fetal death and infectious placental diseases in the mare. *Proc. 26th Ann. Conv. A.A.E.P.* pp.173-179.
43. van Niekerk, C.H. 1965. Early embryonic resorption in mares. *J. South. Afr. Vet. Assn.* 36:61-69.
44. van Niekerk, C.H. and J. C. Morgenthal. 1982. Fetal loss and the effect of stress on plasma progesterone levels in pregnant Thoroughbred mares. *J. Reprod. Fert. Suppl.* 32:453-457.
45. van Niekerk, C.H. and J. S. van Heerden. 1972. Nutrition and ovarian activity of mares early in the breeding season. *J. South Afr. Vet. Assn.* 43:351-360.
46. Villahoz, M.D., E. L. Squires, J. L. Voss and R. K. Shideler. 1985. Some observations on early embryonic death in mares. *Theriogenology* 23:915-924.



## Chapter 4

# UTERINE PATHOLOGY

### Introduction

With ultrasonography, the uterus can be examined noninvasively for pathological changes and to monitor therapeutic regimen(s). The three most common forms of uterine pathology detected by ultrasonography are accumulations of intrauterine fluid, air and cysts. Less commonly, fetal remnants, debris and neoplastic conditions are detected.

### Intrauterine Fluid

Ultrasonography is extremely valuable for estimating quantity and quality of fluid in the uterine lumen. Rectal palpation is only accurate when quantity of intrauterine fluid is large (> 100 ml) and(or) when uterine tonicity changes. Confirmation of intrauterine fluid, without invasive techniques such as lavage and cytological analysis, was difficult until direct, noninvasive visualization was made possible with ultrasonography.

**Table 4-1. Ultrasonographic Evaluation of Uterine Fluid<sup>a</sup>**

Ultrasonographic grade of uterine fluid	Ultrasonographic characteristics of uterine fluid	Gross characteristics of uterine fluid
Grade I <sup>b</sup> (Figure 4-1)	White (strongly echogenic or hyperechoic)	Thick and creamy
Grade II (Figure 4-2)	Light gray (semi-echogenic or hyperechoic)	Milky
Grade III (Figure 4-3)	Dark gray (hypoechoic — few hyperechoic foci suspended in anechoic medium)	Obvious turbidity and sedimentation
Grade IV (Figure 4-4)	Black (anechoic)	Clear

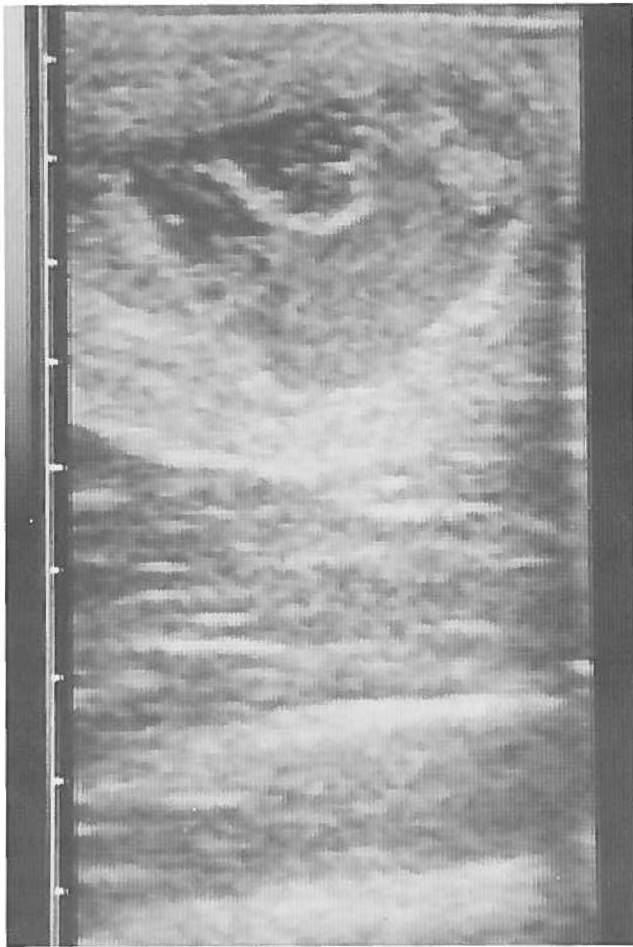
<sup>a</sup> Adapted from (21).

<sup>b</sup> The degree of echogenicity is related to debris and inflammatory material in uterine fluid.

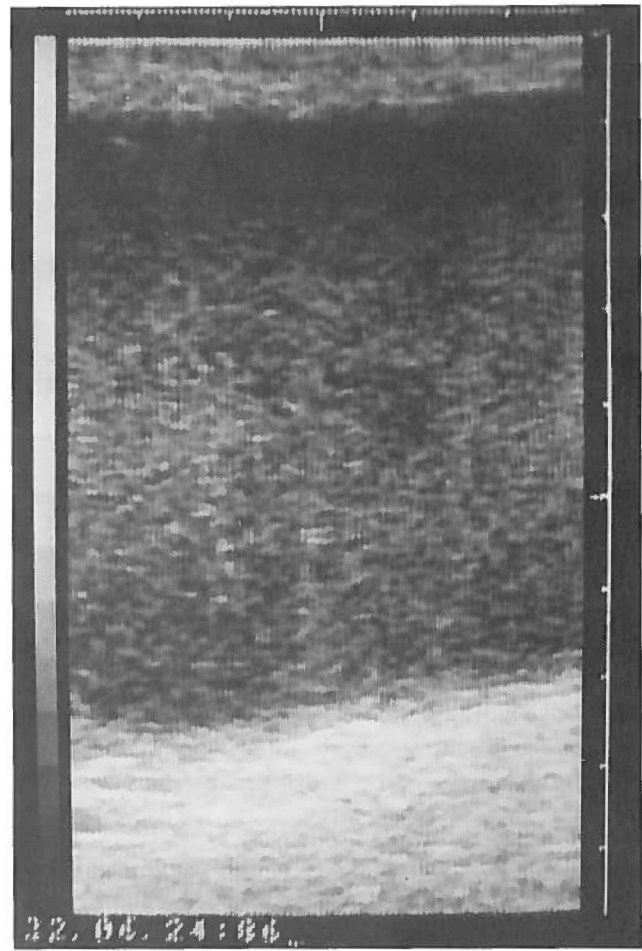
At our laboratory (19,30), volumes of fluid within the uterine lumen are estimated with ultrasonography and quality is graded from I to IV according to degree of echogenicity (Table 4-1; Figures 4-1 to 4-4). Degree of echogenicity is related to amount of debris or white blood cell infiltration into the fluid. Grade I fluid has large numbers of neutrophils and grade IV has very few neutrophils. Observations on quality and quantity of uterine fluid have been used to assess efficacy of various therapeutic procedures on individual animals treated for naturally occurring endometritis. Experiments (20,21) have been conducted to determine the relationship of intrauterine fluid to fertility.

**Ultrasonographic Studies of the Uterus After Parturition.** In the equine industry, economic incentives influence breeders to attempt a foaling interval of 12 mo or less. This commonly necessitates breeding of mares during the first post-partum ovulatory period. However, fertility has been reported lower in mares bred during the first post-partum ovulatory period compared with mares bred during subsequent cycles (4,8,12,14,15), and early embryonic death has been reported higher for mares bred at this time (14,23,26). This decreased fertility may be due to failure of elimination of microbes during uterine involution (2,23,26) or their introduction at breeding (7). In addition, presence of uterine fluid during estrus (19) and diestrus (1,22) has been shown to reduce fertility of mares.

A study (21) was conducted to evaluate two hypotheses: a) uterine involution and fluid accumulation could be effectively monitored with ultrasonography and used to predict fertility of mares bred during the first post-partum ovulatory cycle, and b) delaying ovulation with a progestin would result in improved pregnancy rates in mares bred during the first post-partum ovulatory period.



**Figure 4-1.** Grade I intrauterine fluid — white, strongly echogenic or hyperechogenic.



**Figure 4-2.** Grade II intrauterine fluid — light grey, semi-echogenic or hyperechogenic.

Forty-five mares were randomly assigned as they foaled to one of three treatment groups: group 1 (n = 15), controls; group 2 (n = 15), daily oral treatment with 0.044 mg/kg altrenogest<sup>a</sup> for 8 days beginning the day after parturition and an injection of 10 mg of prostaglandin F2-alpha<sup>b</sup> on day 9; group 3 (n = 15), daily oral treatment with 0.044 mg/kg altrenogest for 15 days, beginning the day after parturition.

Mares were teased daily with one or more stallions (25). Ultrasonographic (intrarectal 5 MHz linear array) examination of each mare's reproductive tract was performed every other day beginning on day 3 and continuing until day 31 after parturition. Ultrasonography was used to measure diameter of the uterus at the tip and middle of the uterine horns and corpus cornual junctions, and to estimate quality (grades I to IV; Table 4-1) and quantity (ml) of uterine fluid. Follicular growth and ovulation were monitored by ultrasonography. The technician performing ultrasonographic examinations was unaware of group assignment,

or any other data on uterine measurements. Control mares were inseminated every other day with 500 million progressively motile **spermatozoa** (25) once a  $\geq 35$ mm (1.38 in) follicle was detected. After withdrawal of treatment, treated mares were inseminated using identical criteria. Mares were inseminated during the first post-partum ovulatory period, regardless of estrous behavioral signs.

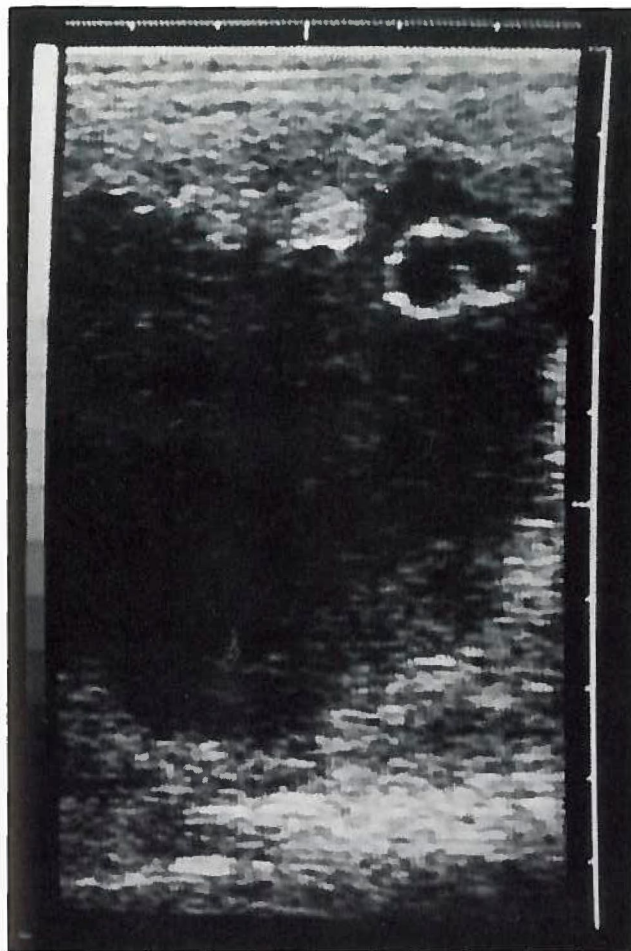
Pregnancy was diagnosed with ultrasonography 12 to 14 days after ovulation and monitored every other day until 20 days of gestation. Because the mares were to be used as embryo donors in a companion study, pregnancy was terminated with PGF2-alpha at day 20. Analysis of variance was used to determine differences between uterine size and mean interval to ovulation among groups. Chi-square analysis was used to evaluate pregnancy data.

The previously gravid horn was larger than the non-gravid horn for a mean of 21 days (range 15 to 25) after parturition. Uterine involution was most obvious at the corpus cornual junction. When the results of three ultrasonographic scans were similar, over a 5-day period, the uterus was considered to be involuted. On the average, uterine involution was completed by day 23 (range 13 to 29).

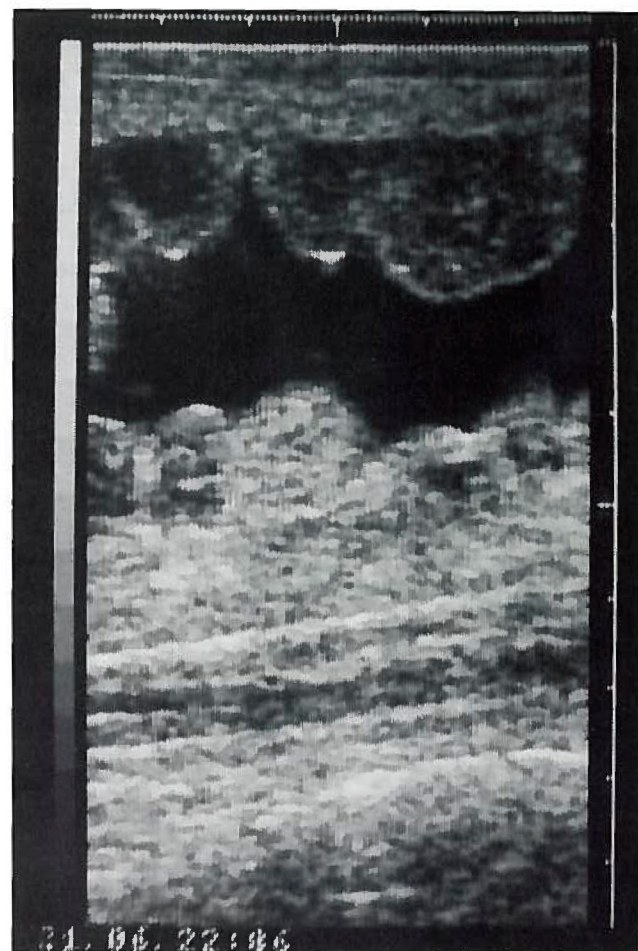<sup>a</sup>Regu-Mate, Hoechst-Roussel Agri-Vet, Somerville, NJ 08876.

<sup>b</sup>Lutalyse, Upjohn Co., Kalamazoo, MI 49001.





**Figure 4-3.** Grade III intrauterine fluid — dark grey, hypoechoic; few hyperechoic foci suspended in an anechoic medium.



**Figure 4-4.** Grade IV intrauterine fluid — black, anechoic.

Quantity and quality of uterine fluid were not affected by progestin treatment (Table 4-2). Number of mares with detectable uterine fluid decreased after day 5 post-partum. Uterine fluid generally decreased in quantity and improved in quality between days 3 and 15.

**Table 4-2. Ultrasonographic Assessment of Uterine Fluid Quantity and Quality in 45 Mares After Parturition<sup>a</sup>**

Post-partum days	No. of mares with detectable uterine fluid	Mean uterine fluid quality (Grade I-IV)
3	34	2.1
5	37	2.8
7	28	3.2
9	11	2.7
11	6	3.3
13	7	3.4
15	2	3.0

<sup>a</sup> Adapted from (21).

Fewer ( $P < 0.005$ ) mares became pregnant when uterine fluid was present during the first post-partum ovulatory period (3 of 9, 33%), compared to when no fluid was detected (26 of 31, 84%). Mares with uterine fluid during breeding did not have appreciably larger uterine dimensions compared with those mares not having fluid. There was no relationship between uterine size on day of ovulation and pregnancy rate. Ovulations were delayed and pregnancy rates improved in progestin-treated mares (Table 4-3). More ( $P < 0.05$ ) mares became pregnant (23/28, 82%) when they ovulated after day 15, in the first post-partum ovulatory period, than mares that ovulated before day 15 (6/12, 50%).

In this study (21), ultrasonography was useful in detecting mares with postpartum uterine fluid. Further, it could be used to aid in determining whether a mare should be bred, treated, or not bred during the first post-partum ovulatory period. During estrus, uterine fluid may be spermicidal and (or) an excellent medium to support bacterial proliferation. When fluid is present during diestrus, it may cause premature luteolysis or EED (1). Quantity of uterine fluid during the first post-partum ovulatory period appeared to be related

**Table 4-3. Mean Interval from Parturition to Ovulation, and Pregnancy Rates for Control and Progestin-Treated Mares Bred During the First Post-Partum Ovulatory Period**

	Group I	Group II	Group III
Mean interval from parturition to ovulation (days)	14.5 <sup>a</sup>	18.2 <sup>b</sup>	23 <sup>c</sup>
No. of mares pregnant/ no. mares bred	9/15	11/12	9/13
Pregnant (%)	(60%) <sup>x</sup>	(92%) <sup>y</sup>	(69%) <sup>x,z</sup>

<sup>a,b</sup> Significantly different ( $P < 0.10$ ).

<sup>b,c</sup> Significantly different ( $P < 0.05$ ).

<sup>a,c</sup> Significantly different ( $P < 0.01$ ).

<sup>x,y</sup> Pregnancy rates with different superscripts are significantly different ( $P < 0.05$ ).

<sup>y,z</sup> Pregnancy rates with different superscripts are significantly different ( $P < 0.10$ ).

to stage of uterine involution, and was reduced or eliminated by delaying the ovulatory period with progestins.

Progestin treatment not only allowed time for elimination of uterine fluid before the first post-partum ovulation, but it also significantly delayed the first post-partum ovulation. Results of this study concurred with those of others in which it was concluded that progestin treatment delayed onset of the first post-partum ovulatory period, but did not affect rate of uterine involution (16,17,27,29). Lower ( $P < 0.10$ ) pregnancy rates in group 3, compared with group 2 (69 vs 92%; Table 4-3) may have been related to effects of prolonged treatment with progestin on uterine defense mechanisms (9,33) in mares in which the uterus was challenged with bacteria associated with foaling or the post-partum period. Long-term progestin administration to normal, cycling mares has not been shown to adversely affect fertility (31).

Since there were decreased pregnancy rates associated with uterine fluid, and increased pregnancy rates as ovulation was delayed, we suggest both techniques could be used to manipulate breeding strategies and improve pregnancy rates of normal mares bred during the first post-partum ovulatory period.

**Effect of Intrauterine Fluid on Pregnancy Rate and Early Embryonic Death.** This study (20) was designed to determine the influence of intrauterine fluid on pregnancy rate and early embryonic death. Endometritis was initiated in 60 progesterone-treated mares by either inoculation with a broth containing  $5 \times 10^7$  (50 million) *Streptococcus zooepidemicus* organisms/ml and(or) repeated uterine invasion during reproductive evaluation. All mares received 150 mg of progesterone in oil daily for 31 days. All reproductive evaluations were performed during this 31-day period. Mares were divided into six treatment groups (n = 10 per group):

**Group 1** — Uninoculated controls

**Group 2** — Inoculated controls

**Groups 3 to 6** — Inoculated plus various systemic and intrauterine therapies.

Seven days after the last treatment, all mares remained infected with either *Streptococcus zooepidemicus* and(or) *E. coli*. At this time, progesterone therapy was withdrawn, which resulted in recrudescence to cyclicity. The hypothesis tested was: mares that had uterine fluid after ovulation, determined by ultrasonography, would have a decreased pregnancy rate and(or) an increased incidence of EED.

Mares were inseminated with 200 million progressively motile spermatozoa every other day during estrus beginning on day 2 or 3 of estrus (25) or once a  $\geq 35$  mm (1.38 in) follicle was detected. Ultrasonography was used to monitor follicular changes, accumulation of intrauterine fluid and pregnancy. Mares were bred only during the first cycle after withdrawal of progesterone.

Pregnancy rate on day 11 was 66% (37/56) compared to 50% (28/56) on day 50. The high rate of EED between days 11 and 50 (9/37, 24.3%) was expected, since all mares had evidence of endometritis at the conclusion of treatment with progesterone.

Fluid in the uterus during estrus did not influence day-11 pregnancy rate (18/24, 75%) compared to pregnancy rate of mares with no fluid (19/32, 59%). Pregnancy rates at day 11 were less when fluid was present 1 or 2 days after ovulation (7/12, 58.3%), but not significantly different ( $P > 0.05$ ) from pregnancy rates of mares with no fluid during estrus (30/44, 68.2%). When fluid was detected at both estrus and day 1 or 2 post-ovulation, pregnancy rates were less at day 11 (4/11, 36.4%), but not significantly different ( $P > 0.05$ ) from rates in mares when fluid was not detected at all (13/21, 61.9%).

No difference in incidence of EED was found between days 11 and 50 for mares with fluid present during estrus (4/18, 22.2%) compared to no fluid observed during estrus (5/19, 26.3%). A significant difference ( $P < 0.02$ ) in rate of EED between days 11 and 50 was found between mares with fluid detected 1 or 2 days after ovulation (5/9, 55.6%), and those that had no fluid during the same time period (2/28, 14.3%).

Intrauterine fluid during estrus had no effect ( $P > 0.05$ ) on day-50 pregnancy rate (15/24, 62.5%), compared to those mares that had no fluid detected (13/32, 40.6%). Fluid 1 or 2 days after ovulation had a significant effect ( $P < 0.05$ ) on day-50 pregnancy rates (3/12, 25.0%) compared to mares that had no fluid detected (25/44, 56.9%).

When fluid was detected during both estrus and 1 or 2 days after ovulation, day-50 pregnancy rates were depressed ( $P < 0.05$ ; 2/11, 18.2%), compared to mares that had fluid detected at either estrus or 1 or 2 days after ovulation (14/24, 58.3%) and mares that had no fluid detected at any time (12/21, 57.1%).

Twenty-seven mares were randomly assigned to ultrasonographic examination on days 2, 4, 6, 8 and daily between days 10 and 20 post-ovulation. For this group of mares, intrauterine fluid significantly depressed pregnancy rates ( $P < 0.005$ ) at day 50 (2/12,

16.7%), compared to pregnancy rates from those mares with no fluid detected during the same period (11/15, 73.3%).

It was concluded from this study that: a) presence of intrauterine fluid during estrus in cycling mares did not affect pregnancy rates at either day 11 or 50; b) intrauterine fluid, 1 or 2 days after ovulation, did not affect day-11 pregnancy rates, but was associated with a significant increase in EED and reduced day-50 pregnancy rates; and c) presence of intrauterine fluid during diestrus (days 1 to 20 post-ovulation) was associated with a significant decrease in day-50 pregnancy rates.

The discrepancy between effect of presence of fluid in the uterus during estrus, compared to the previous study, on mares after parturition may be partially explained by the fact that mares in this study were all diagnosed as having endometritis before cyclicity was initiated. Removal of exogenous progesterone resulted in a rapid return to estrus for most mares (mean 3.0 ± 2.0 days). Detection of fluid during estrus in these mares may not accurately reflect the normal population of mares. Another possibility is that intrauterine fluid during the first post-partum ovulatory cycle may be a medium more conducive to bacterial growth after breeding than fluid present during estrus in cycling mares.

#### **Effect of Intrauterine Fluid on Recovery of Embryos.**

During the 1987 breeding season at our laboratory (20), ultrasonography was used to determine quality of uterine fluid (Table 4-1) and estimate quantity in two groups of normally cycling mares: group 1 — fertile experimental mares (n = 220 cycles), and group 2 — infertile mares (n = 57 cycles). Data were recorded daily during estrus and on day 1 and/or 2 post-ovulation. Effect of quantity and quality of fluid and frequency and stage of cycle, at detection of fluid, on embryo recovery was compared utilizing chi-square analysis. Embryo recovery was attempted either on day 6 or 7 post-ovulation from mares bred by artificial insemination with 200 to 500 million progressively motile spermatozoa (25).

**Group 1, normally cycling mares.** Presence of fluid during estrus, or 1 or 2 days after ovulation, had no effect on recovery of embryos (73/135, 54.1% and 40/79, 50.6%, respectively) compared to recovery of embryos when no fluid was detected at estrus, or 1 or 2 days after ovulation (44/85, 51.8% and 77/141, 54.6%, respectively). In addition, quality of fluid had no effect on recovery of embryos. Quantity of uterine fluid altered recovery of embryos. Significantly fewer (P < 0.05) embryos were recovered when fluid volume during estrus was estimated at ≥ 100 ml (3/11, 27.3%) compared to when fluid during estrus was estimated at < 100 ml (120/209, 57.4%).

**Group 2, infertile mares.** Presence of fluid during estrus, or 1 or 2 days after ovulation also had no effect on recovery of embryos (20/50, 40.0% and 12/33, 36.4%, respectively) compared to when no fluid was detected (2/7, 28.6% and 10/24, 41.7%, respectively).

From this study (20), we concluded that only large quantities (≥ 100 ml) of fluid during estrus affected recovery of embryos. However, it should be noted that grade I or II fluid was rare (n = 3 after ovulation, n = 32 in estrus from both groups). For both groups combined, when the quality of fluid during estrus was grade I or II, grade III or IV, or fluid was not detected at all, embryo recovery was 13/32 (40.6%), 74/146 (50.7%) and 49/98 (50%), respectively. When the quality of fluid detected after ovulation (for both groups combined) was grade I or II, grade III or IV, or fluid was not detected, embryo recovery was 1/3 (33.3%), 22/59 (37.3%) and 86/155 (55.5%), respectively. When inflammation was associated with decreased fertilization rate, the effect was expected to be most pronounced in mares with grade I or II fluid. Unfortunately, the number of mares in this group was quite low, which may have been the reason for not detecting a difference.

Despite the fact that critical studies on effect(s) of quality and quantity of intrauterine fluid during estrus on fertilization rates are lacking, it appears that when small quantities of intrauterine fluid (< 100 ml) are present during estrus and/or after ovulation, embryo-recovery rates are unaffected. It should not be assumed that embryo-recovery rates are related to pregnancy rates in mares with uterine fluid. If intrauterine fluid does not affect fertilization, then its main effect may be on the developing conceptus and maintenance of the corpus luteum (CL). The fluid may result in embryonic death or initiate release of prostaglandin, which destroys the CL or prevents recognition of pregnancy.

**Diagnosis of Endometritis.** There are numerous techniques to diagnose endometritis. However, no technique is completely reliable. The common, currently accepted techniques are: a) rectal palpation, b) vaginal-speculum examination, c) bacterial culture of uterine contents, d) cytological examination of uterine contents, and e) endometrial biopsy.

A study was conducted at our laboratory (20) to examine the efficacy of individual diagnostic techniques to predict endometritis. Sixty intact mares were treated with progesterone for 31 days and 50 were inoculated with a broth containing  $5 \times 10^7$  (50 million) *Streptococcus zooepidemicus* organisms per milliliter. Reproductive evaluations were performed the day progesterone treatment began, 13 days after progesterone treatment began, and 2 and 7 days after the various therapeutic regimens. Thus, within the 60 experimental mares, there were 240 examinations for diagnosis of endometritis. The following criteria were used to assess degree of endometritis: a) ultrasonographic detection of intrauterine fluid, b) vaginal-speculum examination, c) cytological examination of uterine contents, d) culture of uterine contents, and e) acute and chronic inflammatory changes detected by endometrial biopsy. Each individual parameter was assigned a score from 0 to 3 (Table 4-4). The total index score for endometritis of 0 to 18, calculated from summation of each component of the reproductive evaluation (0 to

3, for 6 diagnostic tests), was used as a standard to determine when the mare had endometritis. To determine the efficacy of each diagnostic test, a predictive value for each test was calculated (Table 4-5).

It appeared that two conclusions could be drawn from this experimental model: a) a bacterial culture score of  $\geq 1$  was not as accurate in predicting endometritis as other diagnostic tests, and b) ultrasonographic detection of uterine fluid (score  $\geq 1$ ) was an accurate indicator of endometritis.

**Table 4-4. Score Criteria Used to Diagnose Endometritis**

INDIVIDUAL COMPONENTS OF REPRODUCTIVE EVALUATION			
Ultrasonographic examination		Speculum examination	
Score	Criteria	Score	Criteria
0	No fluid	0	Normal color, cervix closed
1	Any grade IV fluid	1	Cervix relaxed or open, mild reddening, no discharge
2	$\leq 50$ ml of grade I, II, or III fluid	2	Moderate reddening $\pm$ discharge, cervix open
3	$\geq 50$ ml of grade I, II, or III fluid	3	Severe reddening $\pm$ discharge, cervix open
Uterine cytology		Uterine culture	
Score	Criteria	Score	Criteria
0	Normal	0	No growth / light growth, nonpathogen
1	Normal with occasional PMNs <sup>a</sup>	1	Light growth / pathogen
2	PMNs 1-8/hpf <sup>b</sup> $\pm$ bacteria	2	Moderate growth / pathogen
3	Numerous PMNs <sup>a</sup> $\pm$ bacteria	3	Heavy growth / pathogen + 1 score for extra pathogen
Endometrial biopsy (acute)		Endometrial biopsy (chronic)	
Score	Criteria	Score	Criteria
0	Normal	0	Normal
1	Mild suppurative inflammation, grade 1	1	Mild lymphocytic inflammation, grade 1
2	Moderate suppurative inflammation, grade 2	2	Moderate lymphocytic inflammation, grade 2
3	Severe suppurative inflammation, grade 3	3	Severe lymphocytic inflammation, grade 3
TOTAL INDEX SCORE OF ENDOMETRITIS (0-18)			
	Normal	< 3	
	Mild	4-8	
	Moderate	9-13	
	Severe	14-18	

<sup>a</sup>Polymorphonuclear leukocytes

<sup>b</sup>High-power field

**Table 4-5. Predictive Value of Individual Tests to Diagnose Endometritis Based on Two Levels of a Total Index Score for Endometritis**

	Score <sup>a</sup>	Total index score $\geq 5$	Total index score $\geq 8$
		Predictive value (%)	
Ultrasound	$\geq 1$	98.6	94.4
	$\geq 2$	99.2	95.5
	$\geq 3$	100	97.1
Vaginal-speculum examination	$\geq 1$	87.6	83.7
	$\geq 2$	95.5	94.1
	$\geq 3$	100	100
Cytology	$\geq 1$	93.2	86.4
	$\geq 2$	99.1	96.4
	$\geq 3$	100	98.5
Culture	$\geq 1$	74.5	66.1
	$\geq 2$	91.5	85.5
	$\geq 3$	96.8	92.1
Endometrial biopsy — acute changes	$\geq 1$	98.6	92.5
	$\geq 2$	100	97.2
	$\geq 3$	100	100
Endometrial biopsy — chronic changes	$\geq 1$	81.4	73.7
	$\geq 2$	97.6	95.2
	$\geq 3$	100	100

<sup>a</sup> Individual test.

This study has several limitations: a) the model is progesterone-dependent and may not accurately reflect naturally-occurring endometritis. A progesterone-dependent model may result in increased bacterial proliferation, decreased neutrophil numbers and function, and decreased drainage of uterine contents; and b) without an independent standard to determine endometritis (i.e. used to compare the individual tests against a positive or negative diagnosis of endometritis), the predictive value in this study may more accurately reflect each individual component's influence on the total index score. However, we do not believe these limitations detract from the usefulness of ultrasonography to diagnose endometritis. The application of ultrasonography becomes even more apparent because it is noninvasive. All 10 uninoculated, control mares developed endometritis. They had a mean total index score of 10.8, which was not significantly different from inoculated mares with a mean of 11.1. Uterine contamination of uninoculated mares was probably from repeated invasion to collect data. Thus, despite accepted hygienic techniques, invasion of the uterus of progesterone-dominated mares resulted in endometritis.

## Uterine Cysts

Prior to ultrasonography, uterine cysts were most commonly diagnosed from post-mortem examination, and occasionally by rectal palpation (13). More recently they have been diagnosed by hysteroscopy (32) and ultrasonography (11,19,20).

Cysts in the uterus are fluid-filled and apparently have two origins. The histological structures of uterine cysts have been described (3,13). Endometrial cysts arise from endometrial glands (13), and are usually  $\leq 10$  mm (1.39 in) in diameter (13,17). Their incidence and significance is largely unknown. The second form of uterine cysts are lymphatic in origin and generally are larger than endometrial cysts. They are common in older mares (1), and have been associated with both normal and abnormal uterine biopsies (13). Size of uterine cysts may be indicative of origin. In a recent report, large, endometrial, glandular cysts were suspected, but were not substantiated with histological examination (32).

No data has been reported on growth rate of uterine cysts. Despite the occasional large cysts reported (32), it is unlikely that they grow at a similar rate as the early embryonic vesicle (days 10 to 20). When visualized with ultrasonography, cysts are commonly rounded, with irregular borders, and occasionally are multiple or compartmentalized. Movement of the early equine conceptus (days 10 to 16), presence of specular reflection, spherical appearance and growth rate of the embryo may aid in its differentiation from uterine cysts.

The relationship between infertility and uterine cysts is axiomatic. Cysts may impede movement of the early conceptus, restricting the reported ability of the vesicle to prevent luteolysis after day 10 (18). Later in pregnancy, contact between the cyst wall and yolk sac or allantois may prevent absorption of nutrients. This may be more important when considering the report that large uterine cysts are more commonly located at the junction of the uterine horn and body (6,32), which is the most common site of vesicle fixation (10). Finally, cysts are commonly indicative of uterine disease. They may reflect reproductive senility or be associated with endometritis. It has been reported (1) that there is an association between number of uterine cysts, age of mare and endometrial biopsy.

The number of treatments proposed for uterine cysts probably reflects inability of any individual treatment to consistently be useful. Rupture of the fluid-filled structures has been attempted via uterine-biopsy forceps (5,13), surgery (28), fine needle aspiration (24) and puncture via hysteroscopy (24,32). Electrocoagulative removal of cysts has recently been described (6,32). Although the number of treated mares was extremely low ( $n = 6$ ) and the mares were rigorously selected for treatment, this technique may have future application for individuals (6). Endometrial curettage (28) and repeated lavage with warm saline (40 to 45°C = 104 to 113°F) have also been advocated (13). Although

there are no reports on efficiency of these treatments, endometrial curettage and saline lavage are frequently applied to treat the primary problem, which would appear to be lymphatic blockage.

A study was conducted at our laboratory (20) to determine location of uterine cysts and the effect of stage of estrous cycle on growth, shape, size, and gross and histopathological characteristics. Also, infrared radiation therapy was used to determine its effect on the cysts. Ultrasonography was used to identify uterine cysts in 12 cycling mares. Data were recorded on a total of 33 uterine cysts at 3-day intervals for 24 days. Nineteen cysts were  $< 10$  mm (.39 in) in cross-sectional diameter, eight cysts were between 10 (.39 in) and 20 mm (.79 in) and six cysts were  $> 20$  mm (.79 in). Shape of cysts varied from round to elongated. Single, multiple and apparently compartmentalized cysts were observed (Figures 4-5 and 4-6). One cyst appeared to be located **transmurally**. The uterus was divided into six segments, left and right uterine horns, left and right corpus cornual junctions and cranial and caudal uterine body. The number of cysts in each location was 5, 5, 4, 4, 4 and 11, respectively. There was no predisposition of a cer-

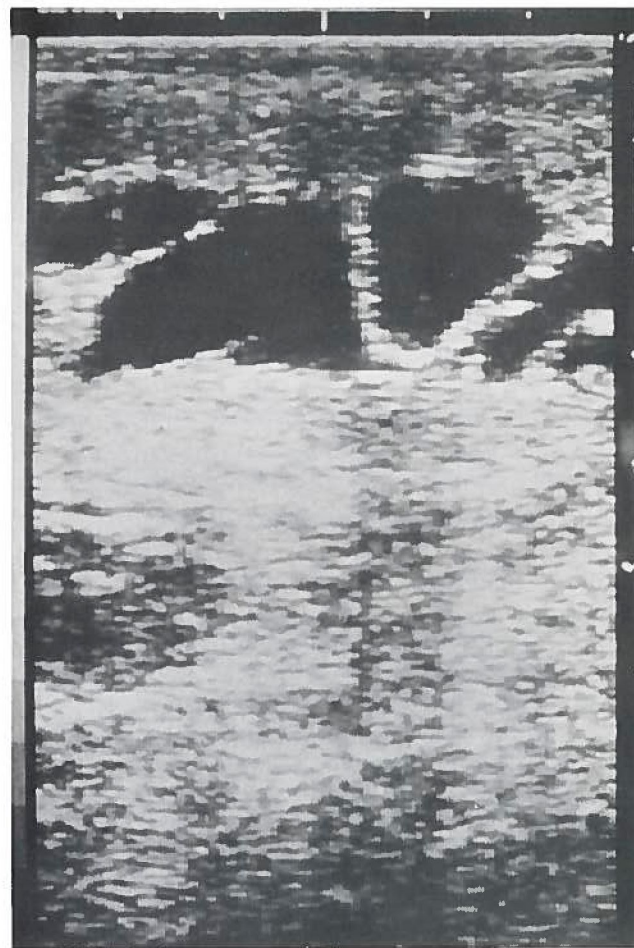
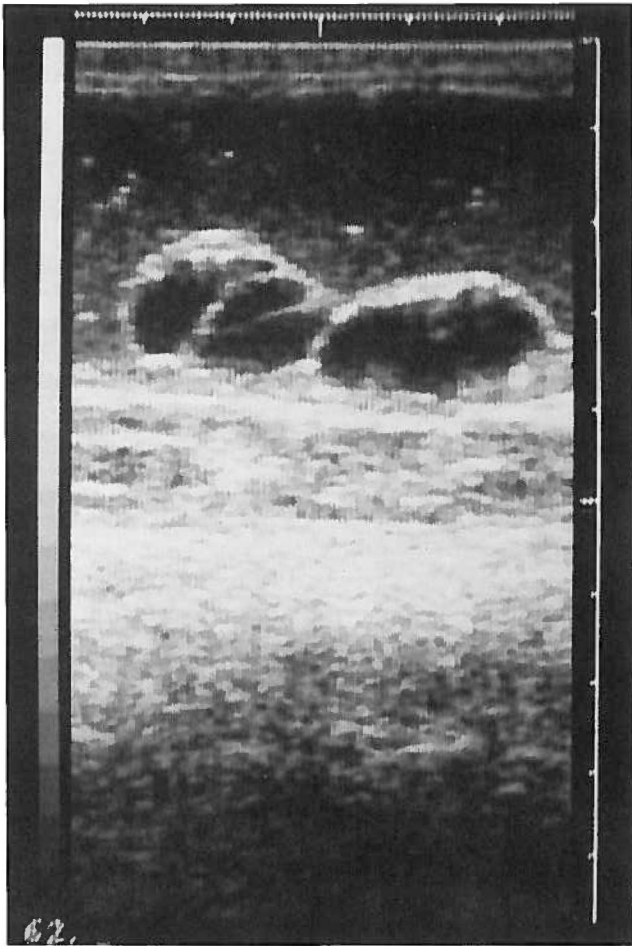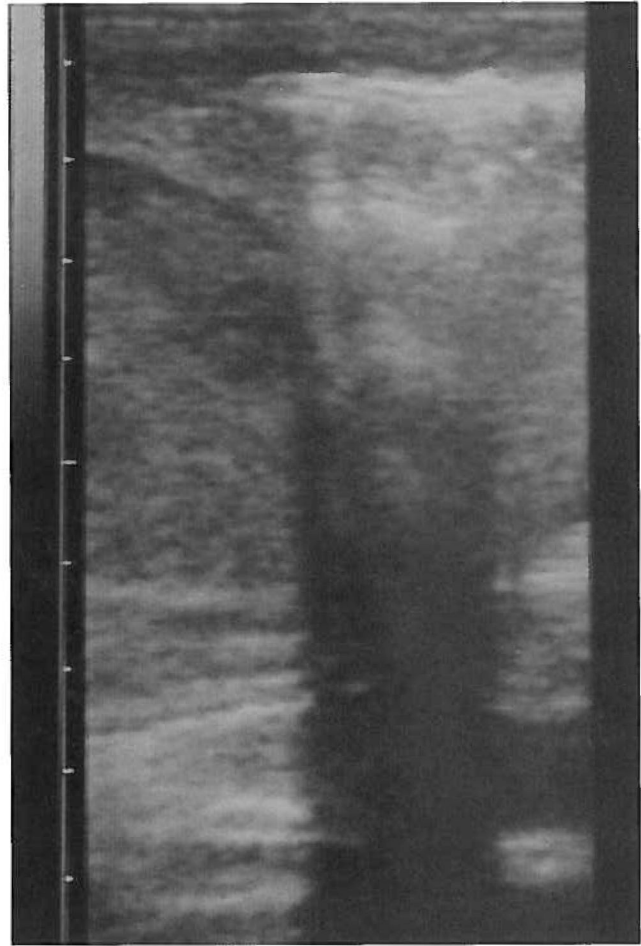


Figure 4-5. Multiple uterine cysts at the corpus cornual junction.



**Figure 4-6.** Multiple, apparently compartmentalized, cysts in the uterine body surrounded by grade II uterine fluid.



**Figure 4-7.** Hyperechogenic reflections slightly cranial to the cervix, characteristic of air.

tain size cyst at any location. Cysts appeared to be distributed randomly throughout the uterus. Eight mares were treated with infrared radiation therapy<sup>c</sup> according to the manufacturer's recommendation. Mares were treated during estrus and examined for a 24-day period. Four mares served as controls. There was no effect of treatment on size, location, shape or histology of cysts. Consequently, data on size, shape, location, changes associated with the estrous cycle and histological examinations have been combined.

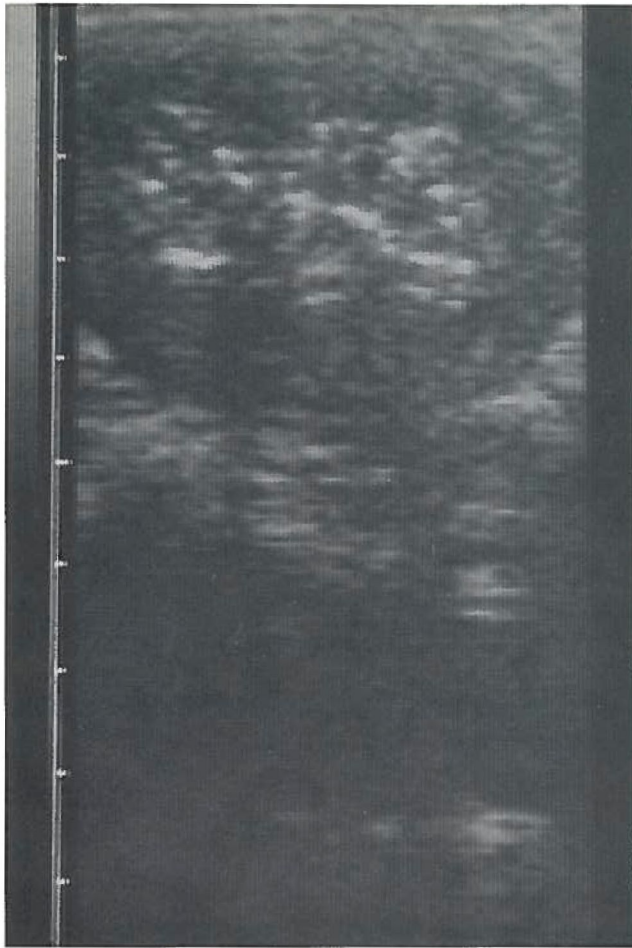
There was no effect of stage of estrous cycle on size of cysts. Mares in estrus had a mean cyst diameter of 12.0 mm (.47 in) compared to 11.9 mm (.47 in) for mares in diestrus. Cysts were occasionally more difficult to discern during estrus, presumably due to presence of endometrial folds. Presence or absence of intrauterine fluid did not affect size or ability to detect uterine cysts. One mare had three cysts that grew from 10 (.39) to 24 mm (.94 in), 22 (.85) to 35 mm (1.34 in), and 25 (.98) to 38

mm (1.50 in), respectively, in cross-sectional diameter during the 24-day examination period.

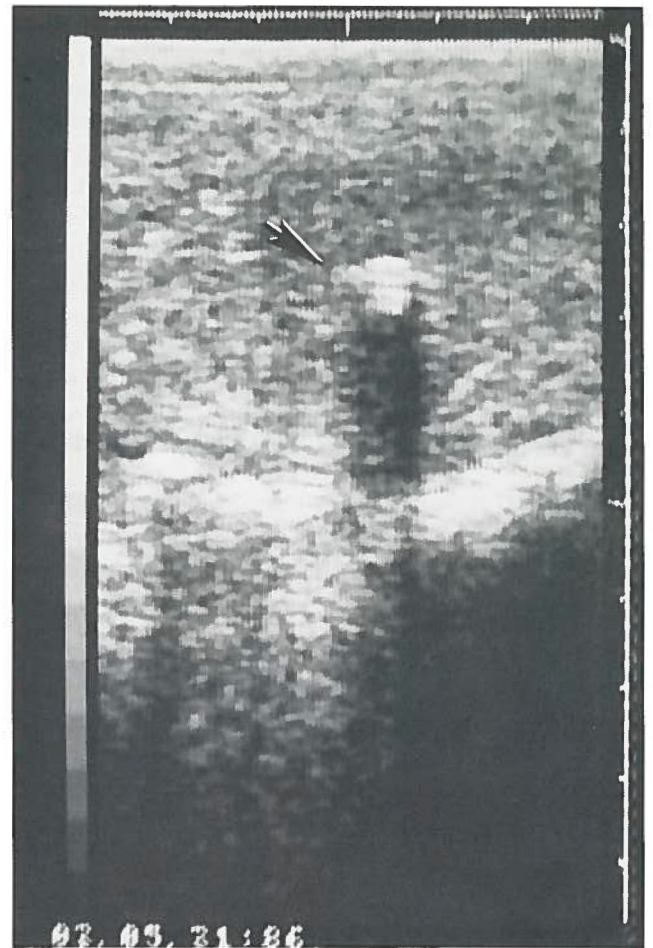
Eighteen uterine cysts from eight mares were examined at necropsy. Endothelial cell lining was found in each cyst, irrespective of size, location, and amount of compartmentalization, including one cyst located transmurally. It was concluded that all cysts detected ultrasonographically were lymphatic in origin. In addition, 6 of the 8 mares (75%) had local distention of lymphatic vessels. Five of eight mares (15/18, 83% of cysts examined at necropsy) had evidence of lymphocytic infiltration, indicative of chronic endometritis. Circumscribed endometrial glands were recorded in four mares. Small glandular cysts were found in the biopsy of one mare (post-mortem). However, these were not visualized by ultrasonography.

We concluded from this study that: a) uterine cysts, when detected by ultrasonography, were lymphatic in origin; b) uterine cysts did not change rapidly in size or shape, although they were more difficult to detect during estrus; c) treatment with infrared radiation was not effective; d) there was no consistent location for uterine cysts; and e) uterine cysts were commonly

<sup>c</sup>Equine Innovations Incorporated, P.O. Box 5375, Loveland, Colorado 80538.



**Figure 4-8.** Hyperechogenic reflections due to air in the uterine horn.



**Figure 4-9.** Ultrasonographic image of a hyperechogenic body in the mare's uterus (arrow). The echo shadow is indicative of dense tissue such as fetal bone.

associated with chronic, infiltrative, lymphocytic endometritis.

### Miscellaneous Uterine Pathology

Recently we have identified other less commonly recognized forms of uterine pathology, the most common of which was air in the uterus. Air is recognized as multiple, hyperechogenic reflections (occasionally a ventral reverberation artifact is present) and it appears to be more prevalent slightly cranial to the cervix (Figure 4-7), although it can be present in the cranial body or uterine horns (Figure 4-8). Air, when present < 24 hrs after artificial insemination, is considered normal. However, it is not expected to be found in normal mares  $\geq$  48 hrs after breeding. The observation of air in the uterus of mares that have not been bred recently is an indication of pneumouterus and reflects failure of the competency of the vaginal labia, vestibulovaginal sphincter and(or) cervix (21).

On occasion, strongly echogenic areas in the uterine lumen are observed with a concomitant echo shadow, such as is seen with dense tissue like fetal bone. This might be expected after mummification (11). We have also identified a similar ultrasonographic image (Figure

4-9) that was confirmed subsequently as the tip of a uterine culturette.

Undoubtedly there are many other forms of less commonly recognized uterine pathology such as uterine neoplasia, abscesses and hematomas that will be recognized as ultrasonography of the uterus becomes more routine.

### SUMMARY

Ultrasonography provides the opportunity to non-invasively examine the uterus to diagnose uterine pathology such as intrauterine fluid, air, uterine cysts and debris. Intrauterine fluid detected during the first post-partum estrus has been associated with significantly decreased pregnancy rates. Large volumes of intrauterine fluid detected during estrus have been associated with decreased embryo recovery rates, and fluid detected after ovulation has been associated with increased EED. Ultrasonography can also be used to monitor therapeutic regimens for treatment of endometritis. Ultrasonography was as accurate as any other diagnostic test for determining the presence of endometritis. In addition, results are available immediately and it does not require invasion of the uterus.

## REFERENCES

1. Adams, G.P., J. P. Kastelic, D. R. Bergfelt and O. J. Ginther. 1987. Effect of uterine inflammation and ultrasonically-detected uterine pathology on fertility in the mare. *J. Reprod. Fert. Suppl.* 35:445-454.
2. Andrews, F.N. and F. F. McKenzie. 1941. Estrus, ovulation and related phenomenon in the mare. *Res. Bull.* #329. Univ. Missouri, Columbia, MO.
3. Arthur, G.H. 1958. An analysis of the reproductive function of mares based on post-mortem examination. *Vet. Record* 70:682-686.
4. Bain, A.M. 1957. Estrus and infertility of the Thoroughbred mare in Australasia. *J.A.V.M.A.* 131:179-185.
5. Baker, C.B. and R. M. Kenney. 1980. Systemic approach to the diagnosis of the infertile or subfertile mare. In: *Current Therapy in Theriogenology*. Ed. D. A. Morrow. W. B. Saunders, Co., Philadelphia, PA.
6. Brook, D. and K. Frankel. 1987. Electrocoagulative removal of endometrial cysts in the mare. *J. Equine Vet. Sci.* 7:77-81.
7. Bruner, D.W. 1951. Notes on genital infection in the mare. *Cornell Vet.* 41:247-250.
8. Caslick, E.A. 1937. The sexual cycle and its relation to ovulation with breeding records of the Thoroughbred mare. *Cornell Vet.* 27:187-206.
9. Evans, M. J., J.M. Hamer, L. M. Gason, C. S. Graham, A. C. Asbury and C.H.G. Irvine. 1986. Clearance of bacteria and non-antigenic markers following intra-uterine inoculation into maiden mares: effect of steroid hormone environment. *Theriogenology* 26:37-50.
10. Ginther, O.J. 1983. Fixation and orientation of the early equine conceptus. *Theriogenology* 19:613-623.
11. Ginther, O.J. and R. A. Pierson. 1984. Ultrasonic anatomy and pathology of the equine uterus. *Theriogenology* 21:505-515.
12. Jennings, W.E. 1941. Some common problems in horse breeding. *Cornell Vet.* 31:197-216.
13. Kenney, R.M. and V.K. Ganjam. 1975. Selected pathological changes of the mare uterus and ovary. *J. Reprod. Fert. Suppl.* 23:335-339.
14. Lieux, P. 1980. Comparative results of breeding on first and second post-foaling heat periods. *Proc. 26th Ann. Conv. A.A.E.P.* pp.129-132.
15. Loy, R.G. 1980. Characteristics of postpartum reproduction in mares. *Vet. Clin. North Am. Large Anim. Pract.* 2:345-359.
16. Loy, R.G., M.J. Evans, R. Pemstein and T.B. Taylor. 1982. Effects of injected ovarian steroids on reproductive patterns and performance in post-partum mares. *J. Reprod. Fert. Suppl.* 32:199-204.
17. Loy, R.G., J. P. Hughes, W.P.C. Richards and S. M. Swan. 1975. Effects of progesterone on reproductive function in mares after parturition. *J. Reprod. Fert. Suppl.* 23:291-295.
18. McDowell, K. J., D. C. Sharp, L.S. Peck and L. L. Cheves. 1985. Effect of restricted conceptus mobility on maternal recognition of pregnancy in mares. *Equine Vet. J. Suppl.* 3:23-24.
19. McKinnon, A.O. and E. L. Squires. 1987. *Equine ultrasound. 5th Annual Short Course Proceedings.* Colorado State Univ. Anim. Reprod. Lab.
20. McKinnon, A.O., E. L. Squires, E. M. Carnevale, L. A. Harrison, D. D. Frantz, A. E. McChesney and R. K. Shideler. 1987. Diagnostic ultrasonography of uterine pathology in the mare. *Proc. 33rd Ann. Conv. A.A.E.P.* pp.605-622.
21. McKinnon, A.O., E. L. Squires, L. A. Harrison, E. L. Blach and R. K. Shideler. 1988. Ultrasonographic studies on the reproductive tract of postpartum mares: effect of involution and uterine fluid on pregnancy rates in mares with normal and delayed first postpartum ovulatory cycles. *J.A.V.M.A.* 192:350-353.
22. McKinnon, A.O., E. L. Squires and J. L. Voss. 1987. Ultrasonic evaluation of the mare's reproductive tract: Part II. *Comp. Cont. Educ. Pract. Vet.* 9:472-482.
23. Merkt, H. and A. Gunzel. 1979. A survey of early pregnancy losses in West German Thoroughbred mares. *Equine Vet. J.* 11:256-258.
24. Neely, D.P. 1983. *Equine Reproduction.* Veterinary Learning Systems Co. Inc., Princeton Junction, NJ.
25. Pickett, B.W., E. L. Squires and A. O. McKinnon. Procedures for collection, evaluation and utilization of stallion semen for artificial insemination. *Colorado State Univ. Anim. Reprod. Lab. Bull. No. 03.*
26. Platt, H. 1973. Aetiological aspects of abortion in the Thoroughbred mare. *J. Compar. Pathol.* 83:199-205.
27. Pope, A.M., D. L. Campbell and J. P. Davidson. 1979. Endometrial histology of post-partum mares treated with progesterone and a synthetic GnRH (AY-24,031). *J. Reprod. Fert. Suppl.* 27:587-591.
28. Rosedale, P.D. and S. W. Ricketts. 1980. *Equine Stud Farm Medicine.* 2nd ed. Lea & Febiger, Philadelphia, PA.
29. Sexton, P.E. and F.M. Bristol. 1985. Uterine involution in mares treated with progesterone and estradiol 17-B. *J.A.V.M.A.* 186:252-256.
30. Squires, E.L., A. O. McKinnon and R. K. Shideler. 1988. Use of ultrasonography in reproductive management of mares. *Theriogenology* 29:55-70.
31. Squires, E.L., R. K. Shideler, J. L. Voss and S. K. Webel. 1983. Clinical applications of progestins in mares. *Comp. Cont. Educ. Pract. Vet.* 5:16-22.
32. Wilson, G.L. 1985. Diagnostic and therapeutic hysteroscopy for endometrial cysts in mares. *Vet. Med.* 80:59-63.
33. Winter, A.J. 1982. Microbial immunity in the reproductive tract. *J.A.V.M.A.* 181:1069-1073.



nd L. L.  
tus mo-  
ancy in  
  
Equine  
oceed-  
. Lab.  
le, L. A.  
rd R. K.  
phy of  
d Ann.  
  
n, E. L.  
raphic  
artum  
uid on  
elayed  
M.A.  
  
. 1987.  
uctive  
. Vet.  
  
early  
bred  
  
inary  
tion,  
  
non.  
iliza-  
tion.  
Bull.  
  
r the  
199-  
  
979.  
ares  
RH  
1.  
itud  
del-  
  
olu-  
and  
  
ler.  
ive  
70.  
K.  
; in  
22.  
ys-  
et.  
  
o-

## Chapter 5

# FOLLICULAR DYNAMICS PRECEDING AND DURING OVULATION

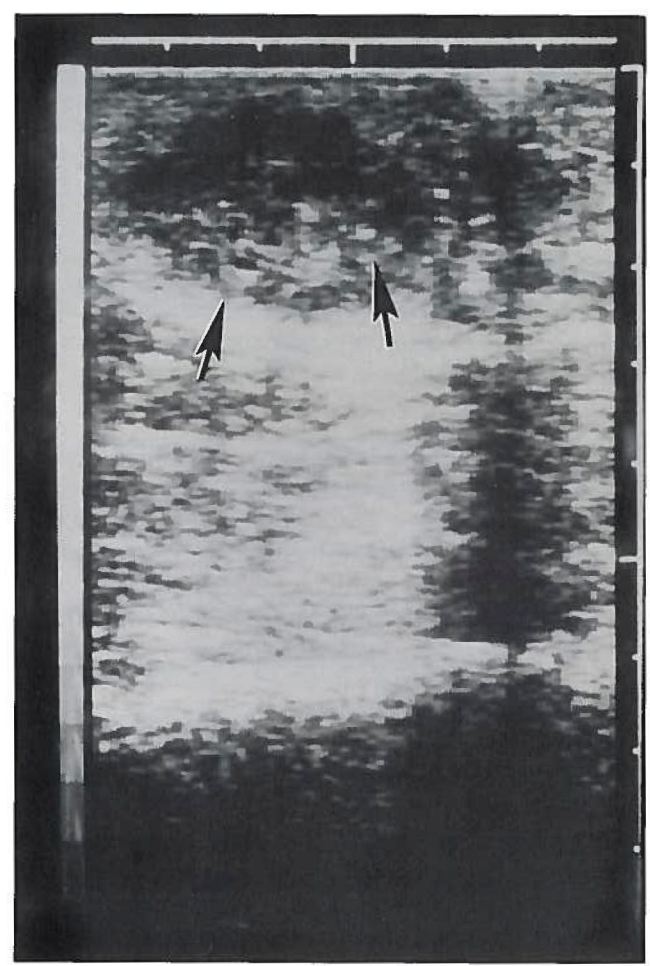
### Introduction

Ultrasonography is useful for monitoring dynamic follicular and luteal changes of equine ovaries, since it permits rapid, visual, noninvasive access to the reproductive tract. A 5 MHz transducer has greater resolution and is more suitable for evaluation of ovaries than a 3 or 3.5 MHz transducer. Follicles as small as 2 to 3 mm (.08 to .12 in) can be seen (5,7), and the corpus luteum (CL) can usually be identified throughout its functional life(16). Potential applications of ultrasonographic examination of the ovaries include: a) estimating stage of estrous cycle, b) assessing preovulatory follicles, c) determining ovulation, d) examining the CL, and e) diagnosing ovarian abnormalities and pathology.

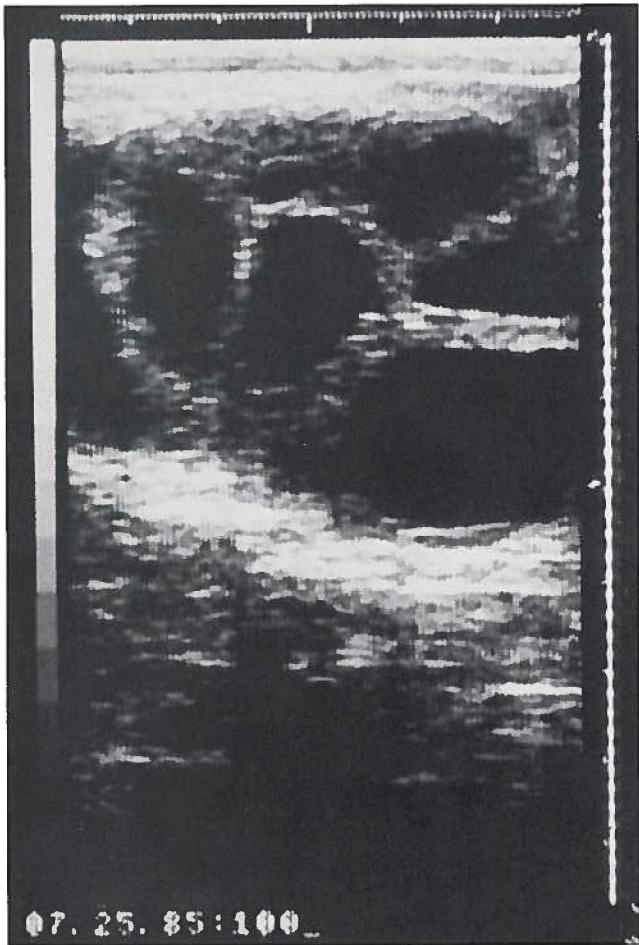### Stage of the Estrous Cycle

Follicles, like other fluid-filled structures, are non-echogenic and appear as black, roughly circumscribed ultrasonographic images (Figures 5-1 to 5-5). Compression by adjacent follicles, luteal structures or ovarian stroma often can result in irregularly-shaped follicles. The apposed walls of adjacent follicles are often straight. Diameter can be estimated by adjusting an irregularly-shaped follicle to an approximately equivalent circular form.

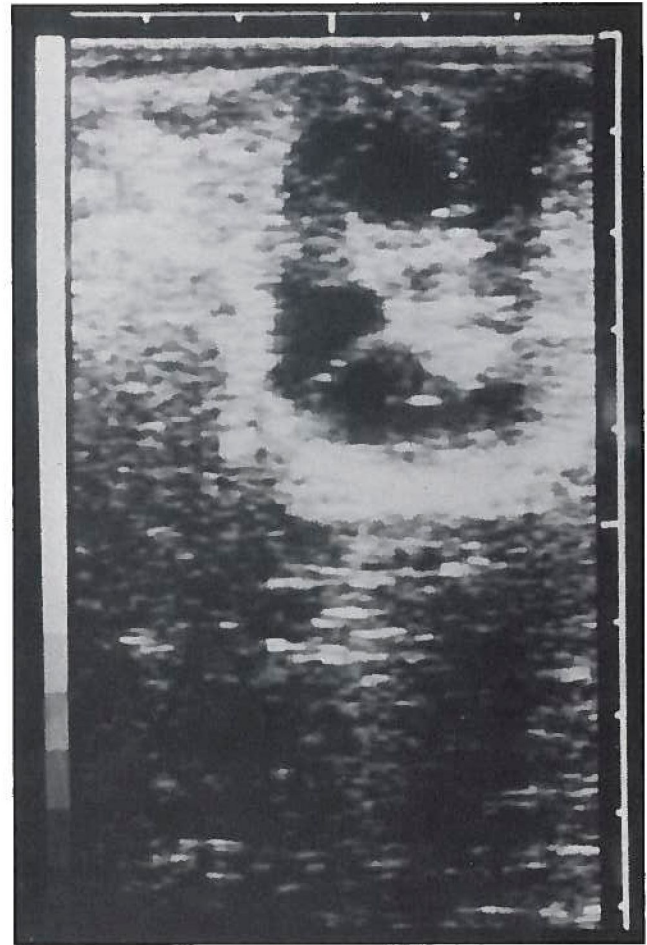
Sequential monitoring of dynamic changes in a follicular population during the estrous cycle has been made possible by ultrasonography (19). During **anestrus**, inactive ovaries are readily differentiated from functional ovaries with ultrasonography. Occasional small follicles (2 to 5 mm; .08 to .20 in) may be present but absence of an ultrasonographically visible CL is characteristic of an anestrus condition (Figure 5-1).



**Figure 5-1.** Ultrasonographic characteristics of an anestrus ovary (ovary delineated by arrows).



**Figure 5-2.** Ultrasonographic characteristics of multiple follicles in an ovary of a mare in transitional estrus.



**Figure 5-3.** Ultrasonographic characteristics of small follicles in an ovary of a mare in early diestrus.

Multiple large follicles (Figure 5-2), characteristic of **transitional** mares prior to their first ovulation of the year, are particularly frustrating to researchers and practitioners. Generally, follicular atresia and subsequent growth occurs until one follicle becomes dominant and ovulates. During transition, some ovulations are difficult to detect by palpation and in these cases, ultrasonographic observation of a CL may confirm whether the mare has entered the ovulatory season. With the use of a 5 MHz transducer, the CL should be ultrasonographically visible for at least 16 days after ovulating (16).

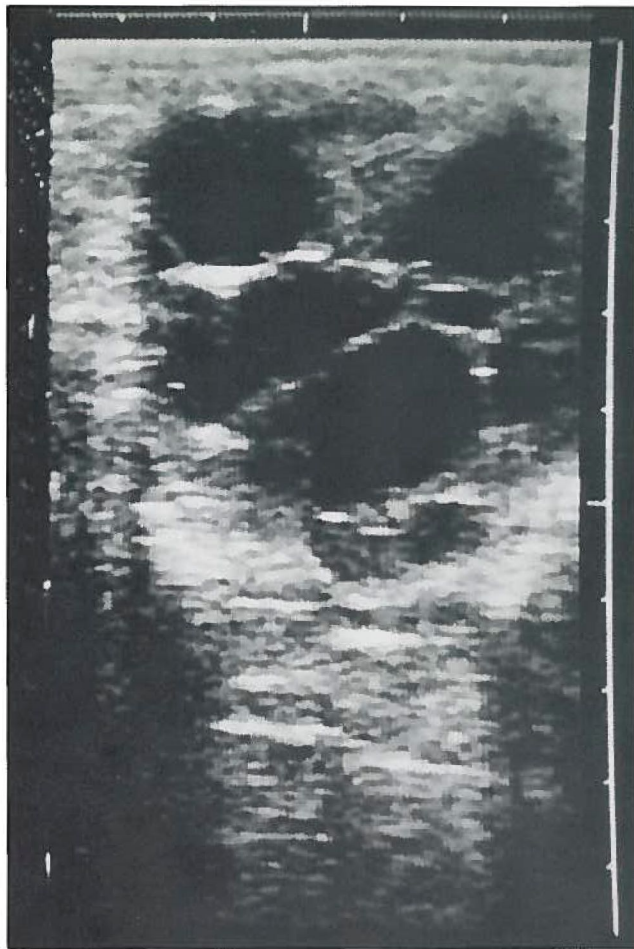
Examination with ultrasonography has resulted in confirmation of the presence of many 5 to 10 mm (.20 to .39 in) follicles during early **diestrus** (Figure 5-3), growth of large follicles at mid cycle, observation of selective, accelerated growth of an **ovulatory** follicle beginning 6 days before ovulation, and regression of large nonovulatory follicles a few days before ovulation (6).

Ultrasonographic examination of the ovaries should not replace sound management techniques such as regular teasing and rectal palpation to determine stage of estrous cycle; rather, it should be used as a powerful ancillary aid.

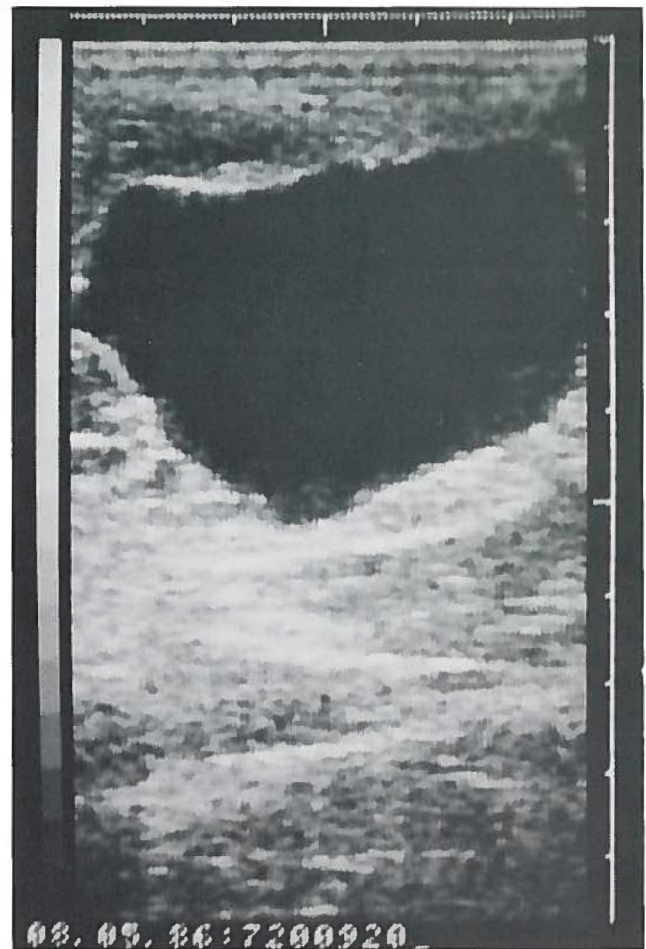
### Preovulatory Follicles

The ability to accurately detect time of ovulation has significant practical application. Selective growth of a single preovulatory follicle is initiated about 6 days before ovulation (17). Various characteristics can be used, within certain limitations, to predict time of ovulation. Softening of the follicle commonly occurs within 24 hrs of ovulation in approximately 70% of mares (14). Ultrasonographically, this is frequently associated with a change in follicular shape (Figure 5-6) from spherical to pear or irregular shapes (17), which may be due to disruption of ovarian stroma as the follicle progresses toward the fossa in preparation for ovulation, i.e. oocyte release.

The mare's ovary is structurally inverted, in comparison to most species, with the exception of the ovulation fossa, which is a 0.5 to 1 cm (.20 to .39 in) depression on the lesser curvature (1). The tunica albuginea and mesovarium forms a thick serosal coating covering the ovarian surface. Connective-tissue tracts extend from the ovulation fossa to the periphery, which forces the follicle to grow centrally toward the fossa (18). These structural arrangements restrict ovulation to the ovulation fossa. Cinematographic and histologic studies have been used to determine the exact location of



**Figure 5-4.** Ultrasonographic characteristics of follicles in an ovary of a mare during late diestrus.



**Figure 5-5.** Ultrasonographic characteristics of a large preovulatory follicle.

follicular rupture (20,21). However, time sequence and follicular changes during ovulation are not well-characterized.

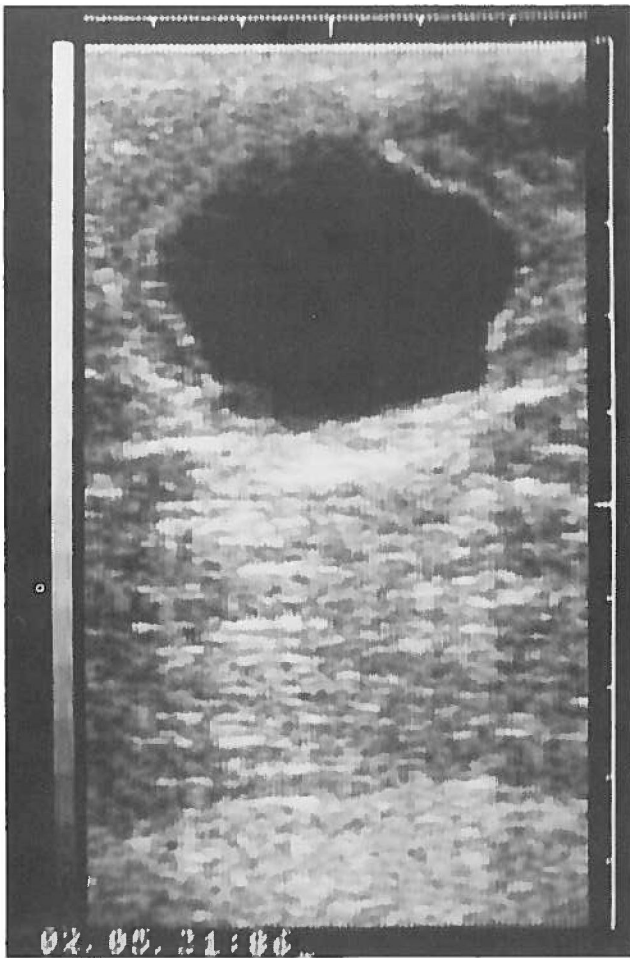
Although stallion semen has been reported to survive for 5 days or longer in the mare's reproductive tract (13,15), it is more commonly accepted that a lapse of > 48 hrs after breeding will result in decreased numbers of viable spermatozoa and reduced fertility (15). Use of frozen, cooled or poor quality semen may markedly hinder life span of spermatozoa after insemination. Although no critical studies have been performed, the mare's oocyte probably begins to lose viability within 12 to 24 hrs after ovulation (15). In addition, semen deposited in the uterus after ovulation requires time to reach the oviduct (site of fertilization) and for **capacitation**. Breeding or insemination, particularly with semen of reduced longevity, just prior to ovulation would maximize pregnancy rates and prevent overuse of an individual stallion.

Accurate prediction of impending ovulation would allow for collection of mature equine oocytes for *in vitro* fertilization or for gamete transfer from infertile mares (2,10,12). In addition, recently ovulated oocytes or early cleavage embryos could be recovered from the oviduct at specific times post-ovulation.

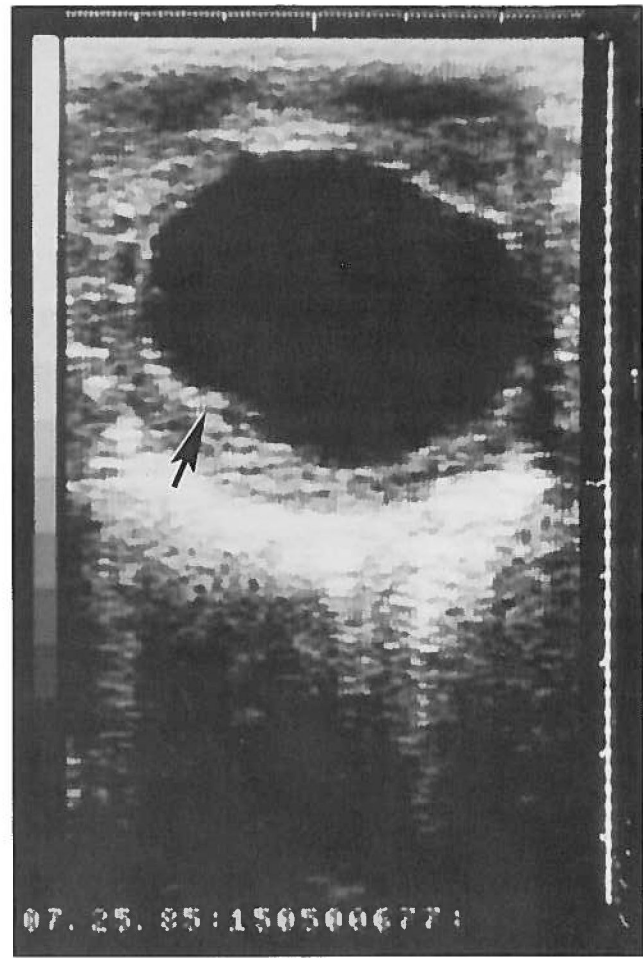
In one study (17), various criteria such as percentage change in shape, size of follicle, echogenicity of follicular fluid and wall, and thickness of follicular wall were evaluated in their ability to predict time of ovulation. Size of the preovulatory follicle was as accurate as any method in determining ovulation time. Generally, double preovulatory follicles ovulated after attaining a smaller maximum diameter than single preovulatory **follicles**.

Thickening of the follicular wall occurs in most preovulatory follicles prior to ovulation (Figure 5-7). However, it generally occurs too early to be an adjunct to predicting ovulation. Increased echogenicity of follicular fluid is sometimes seen prior to ovulation (Figure 5-8), perhaps due to degeneration and subsequent shedding of granulosa cells from the follicular wall. This can be an indicator of impending ovulation, although it is neither common nor consistent enough to be particularly diagnostic.

In summary, the combination of softening of a large follicle, particularly when associated with pain as determined by rectal palpation, and a substantial change in shape of the follicle, as detected with ultrasonography, can be used to predict ovulation within a 24-hr period for most mares.



**Figure 5-6.** Ultrasonographic characteristics of an irregularly-shaped preovulatory follicle.



**Figure 5-7.** Ultrasonographic characteristics of thickening of the follicular wall (arrow) as sometimes seen prior to ovulation.

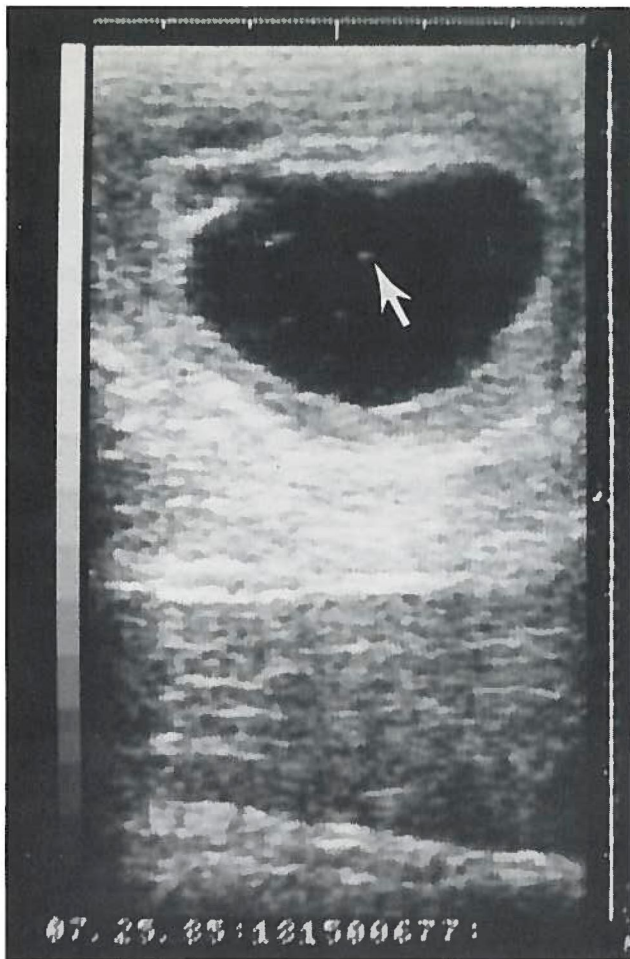
### Characteristics of Ovulation

During 1985 and 1986, a study (3) was performed at our laboratory to determine ultrasonographic characteristics of ovulation. Fifteen light-horse mares were assigned to the experiment upon acquiring the following preovulatory, follicular parameters: a) diameter of  $>40$  mm (1.57 in), b) marked softening upon palpation per rectum, c) pain upon palpation, and d) a change in shape from round to irregular. Preovulatory follicles were observed at  $<1$ -hr intervals for 12 hrs or continually when there were signs of impending ovulation. Ovulation was defined as a rapid decrease in follicular size characterized by disappearance of the large, fluid-filled, nonechogenic structure. A real-time, B-mode, linear array scanner with a 5 MHz transducer was used for ultrasonographic examinations. During ovulation, the ovary was not manipulated or palpated other than to position it for ease of visualization. An attempt was made to stabilize the ovary in the same position during each examination. Images and times were recorded on videotape and analyzed later for changes in follicular appearance, size and shape.

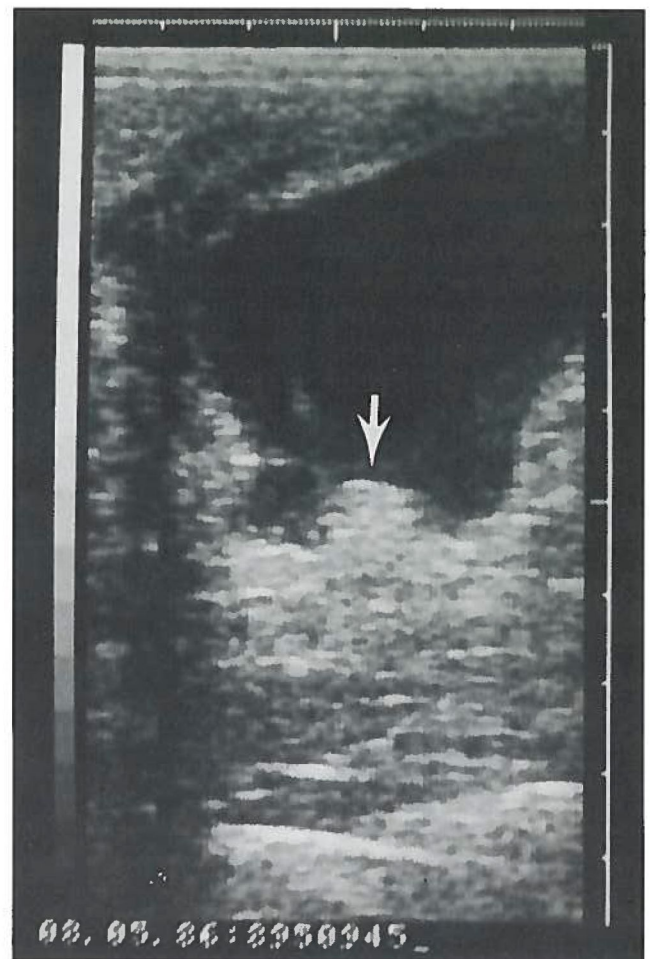
Thirteen of 15 mares ovulated within the 12-hr examination period (mean = 85 min; range 15 min to 3 hrs 37

min after beginning of observation). As ovulation approached, flattened or irregular images (Figures 5-6, 5-7 and 5-8) of the follicles were noted, concomitant with reduced follicular tone. This was likely due to diminished tensile strength of the follicular wall or perhaps a slow release of fluid from the follicle, although no fluid was visualized outside the follicle as ovulation approached. An echogenic nodule, approximately 5 to 10 mm (.20 to .39 in), was noted within the follicles of two mares prior to ovulation (Figure 5-9). These may have represented the cumulus oophorus, which has previously been visualized in women(8). Follicular size decreased 13% from 44 x 17 mm (1.73 x .67 in) 30 min prior to ovulation to 41 x 21 mm (1.61 x .83 in) at ovulation.

Prior to ovulation, 10 of 13 follicles developed a tear in the follicular wall, which was characterized by a jagged protrusion of the follicular border toward the ovulation fossa (Figure 5-10). The remaining three follicles formed a smooth-bordered projection toward the ovulation fossa resulting in a pointed appearance. In seven mares, the tear or point was first observed an average of 41 min (range 15 to 77) prior to ovulation, and was a consistent indicator of impending ovulation.



**Figure 5-8.** Echogenic debris (arrow) in follicular fluid.



**Figure 5-9.** An echogenic nodule that is presumed to be the cumulus oophorus (arrow). This is occasionally detected on the follicular wall prior to ovulation.

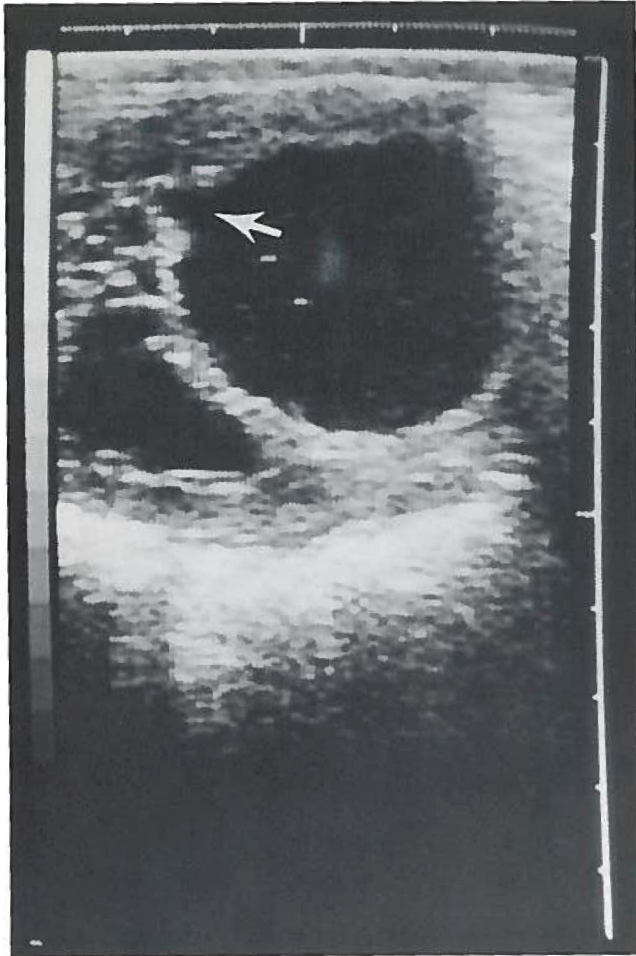
In the remaining mares, a tear or point was already present in the follicular wall upon initial examination. In these mares, ovulation occurred within 3 to 27 minutes. A tear or pointed appearance, observed with ultrasonography just prior to ovulation, is likely due to breakdown of ovarian stroma and protrusion of the follicle toward the ovulation fossa. These observations probably parallel deterioration of the follicular wall, stigma formation and protrusion of the basement membrane just prior to ovulation, as observed in other species (4). Witherspoon and Talbot (21) observed deep layers of ovarian connective tissue that had ruptured. Also, there were surface cuboidal and columnar cells in the area of the ovulation fossa after ovulation. When the ovary was exposed by laparotomy, just prior to ovulation, tearing of a few strands of tissue on the external surface and protrusion of the follicle into the fossa was occasionally visualized (20,21).

Ovulation, defined as a rapid decrease in follicular size (Figures 5-11a to 5-11j), occurred in an average of 42 sec (range 5 to 90). Little or no follicular fluid remained in the follicle after ovulation. Two mares failed to ovulate within 12 hrs after initiation of scan-

ning and subsequently formed anovulatory hemorrhagic follicles (AHF). This occurrence was possibly due to season (11). It should be recognized that mares were chosen for this experiment based on follicles with similar preovulatory characteristics. It is possible that all mares will not exhibit the same ultrasonographic characteristics prior to ovulation. In addition, abnormal ovulations such as AHFs and luteinized, unruptured follicles (9) may initially display a similar sequence of events as normal, preovulatory follicles without ovulation. This was characteristic of two AHFs in the present study.

Follicular fluid was not visualized in the oviduct or uterine horn immediately after ovulation. Witherspoon and Talbot (21) demonstrated, by placing dye within the preovulatory follicle, that follicular fluid entered the oviduct. However, due to a small oviductal lumen, large volumes of follicular fluid and a rapid rate of follicular collapse, it is unlikely that all fluid enters the oviduct.

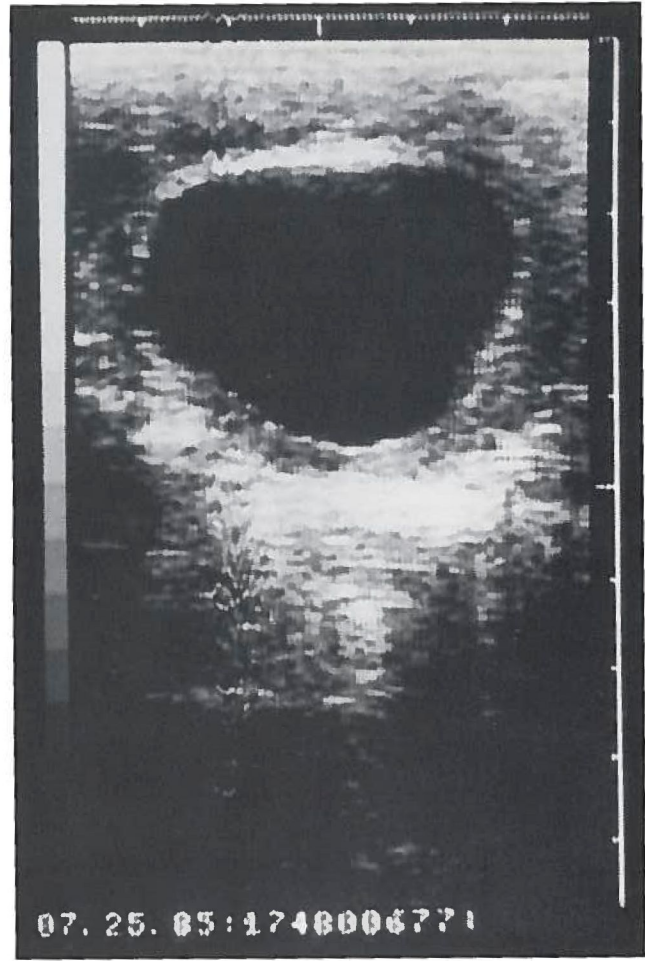
Failure to observe fluid in the oviducts during or after ovulation is not surprising. Firstly, the oviduct at the fimbrial end is small (5 to 10 mm; .20 to .39 in) and a



**Figure 5-10.** A follicle just prior to ovulation. Note the presence of a pronounced neck-like process of the follicular wall (arrow), and increased echogenicity of follicular fluid.

sphincter-like structure would seem to preclude rapid entry of fluid necessary for dilation. Secondly, it is assumed that fluid exit from the follicle is responsible for passage of the oocyte and surrounding cumulus oophorous into the oviduct. However, the fimbria has fine cilia that may facilitate capture and transport of the sticky, gelatinous cumulus oophorous into the oviduct. We have observed a pregnancy in a mare when an oocyte was not recovered by aspiration from a preovulatory follicle. In this case it appeared that despite the loss of follicular fluid, the cumulus oophorous and oocyte were captured by the fimbria, transported into the oviduct and subsequently fertilized.

Increased echogenicity of the follicular wall was visualized in all follicles prior to ovulation (Figures 5-7 and 5-8). Appearance of echogenic "spots" within the follicular fluid, probably due to dispersal of granulosa cells, was noted in 7 of 13 follicles (54%; Figure 5-8). However, echogenic "spots" within follicular fluid, or a bright, echogenic follicular border, were not consistently useful in predicting time of ovulation. A bright echogenic border, irregular shape and a tear in the follicular wall were predictive of imminent ovulation.



**Figure 5-11a.** The process of ovulation recorded by ultrasonography. Preovulatory follicle 50 min prior to beginning of ovulation.

It is important to note that these data may have been biased because only follicles with certain characteristics were chosen for observation. It is quite possible that follicles without these characteristics could have ovulated without observation.

**Facing page:**

**Figure 5-11b.** Preovulatory follicle 30 min prior to the beginning of ovulation. Note rent in dorsal follicular wall (arrow).

**Figure 5-11c.** Preovulatory follicle 20 min prior to beginning of ovulation. Note decrease in follicular size.

**Figure 5-11d.** Preovulatory follicle 15 min prior to beginning of ovulation.

**Figure 5-11e.** The beginning of ovulation. Ovulation has been defined as a rapid decrease in follicular size.

**Figures 5-11f to j.** The process of ovulation over approximately 60 seconds.

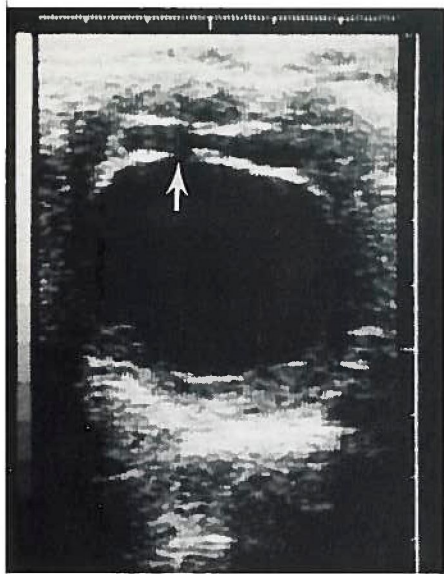


Figure 5-11b.

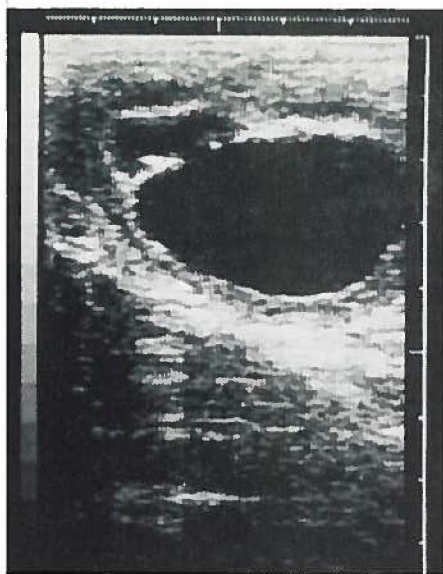

Figure 5-11c.

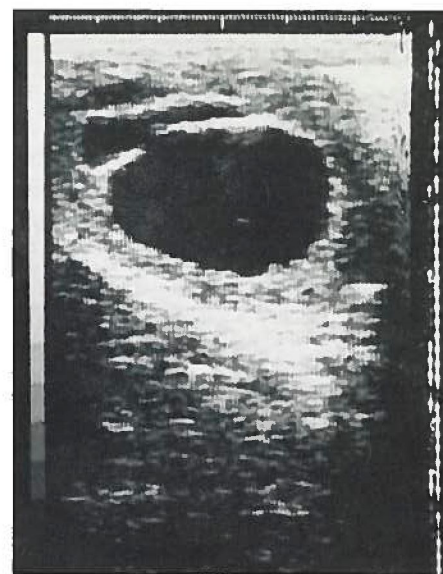


Figure 5-11d.

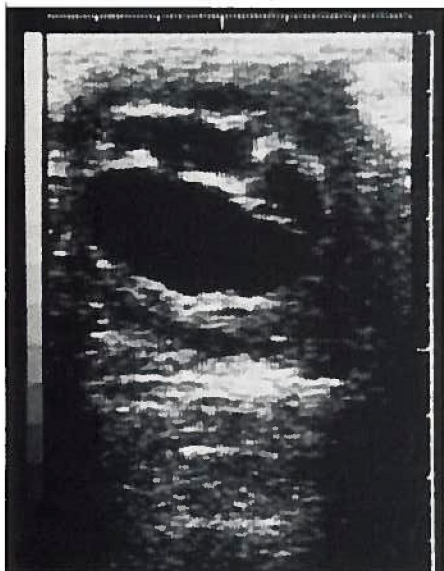


Figure 5-11e.

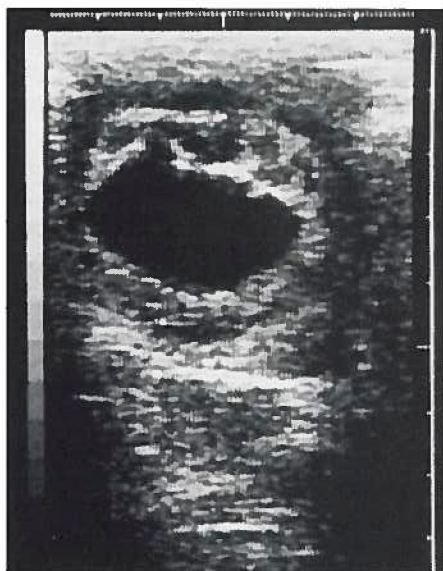


Figure 5-11f.

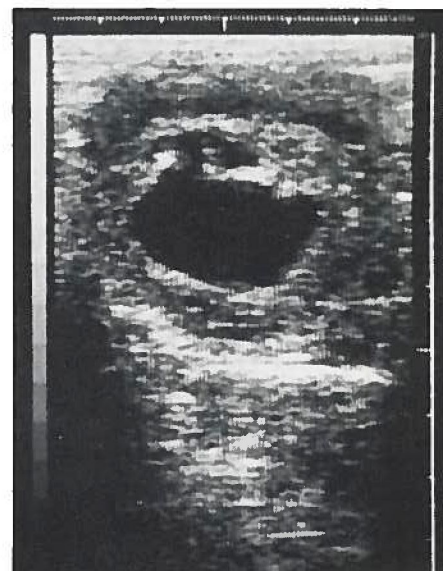

Figure 5-11g.

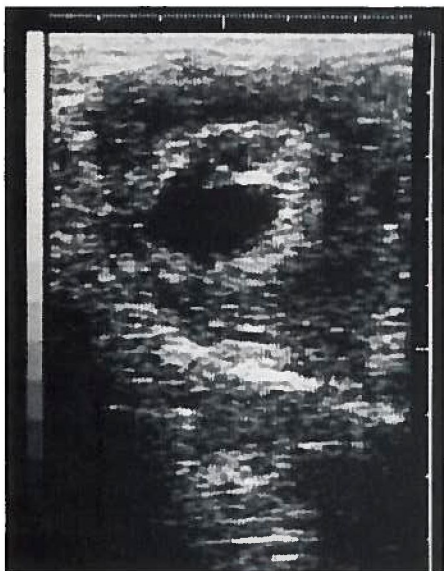


Figure 5-11h.

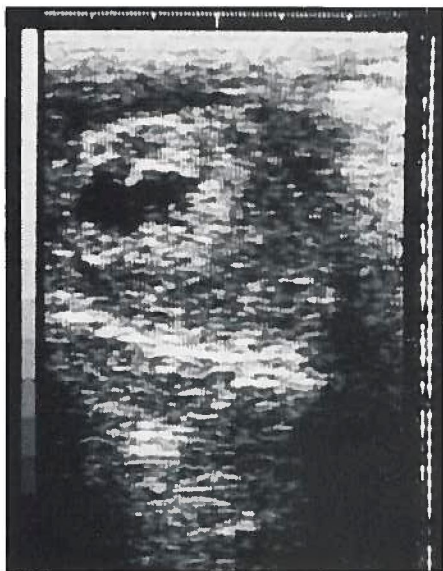


Figure 5-11i.

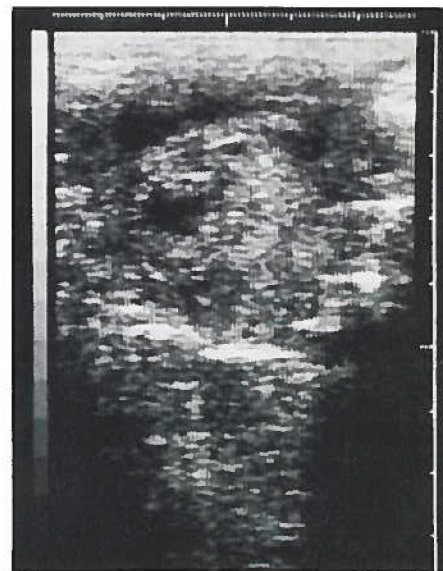


Figure 5-11j.

## Efficacy of Ultrasonography for Determining Ovulation

In a study conducted in our laboratory (19), the accuracy of rectal palpation and ultrasonography for detection of ovulation were compared. Thirty-four normally cycling, nonlactating mares of light-horse breeds were used. Data collection began on day 2 of estrus or when a > 35 mm follicle was detected by palpation. The mares were palpated rectally and scanned every 12 hours. Rectal palpation was performed by one technician and ultrasonographic scanning by a second, each unaware of the diagnosis made by the other. A 3 MHz, linear array, real-time ultrasonographic scanner was used in the study. Mares that ovulated, based on palpation, but which had a second ovulatory-sized follicle, continued to be palpated until a second ovulation occurred or the mare returned to estrus. The length and width of each ovary as well as diameter of each follicle was determined utilizing both methods. The technician utilizing rectal palpation defined ovulation as absence of the follicle and a soft, sometimes painful indentation. Ovulation based on ultrasonography was defined as a change in the echogenic pattern characterized by disappearance of the large, black, fluid-filled, nonechogenic structure and the presence of an echogenic area. For this study, the results of ultrasonographic examinations were assumed to be an accurate indication of ovulation.

In 24 of 34 mares, ovulation was detected at the same time by both methods. Three ovulations were detected by ultrasonography 12 hrs prior to detection by palpation and five ovulations were detected with ultrasonography 12 hrs after detection by palpation. Thus, within  $\pm$  12 hrs, ovulation was detected by both methods in 32 of 34 mares. In one mare, detection of ovulation by ultrasonography occurred 36 hrs prior to detection by palpation. In addition, ovulation was detected by ultrasonography in one mare, but the technician failed to detect ovulation in this same mare by palpation. Although confirmation of ovulation by progesterone analysis was not performed in this mare, estrus ceased approximately 2 days after the ultrasonographic detection of ovulation.

Double ovulations were detected by ultrasonography in 3 of 34 mares. These ovulations occurred on the same ovary within 12 hours. These double ovulations were not diagnosed by rectal palpation. It may be that close apposition of two follicles on one ovary was responsible for failure of the palpator to recognize both structures. The recognition of double ovulation is important to prevent twin pregnancies, and in an embryo transfer program for correct scheduling of recipient mares.

Although ultrasonographic scanning of mares' ovaries should not be used as a replacement for rectal palpation, it is obvious there are occasions when this technique may be more accurate. Even with daily, manual ovarian examination, there are times when ovulation(s) cannot be accurately determined. Use of

ultrasonography in these circumstances allows one to make a more accurate determination concerning ovulation. In cases where ovulation is detected by ultrasonography and not by palpation, it is most commonly associated with a well-circumscribed developing structure, which although smaller, has palpation characteristics similar to that of a fluid-filled follicle. These structures either collapse and refill with blood to form a corpus hemorrhagicum (Chapter 6) or apparently fail to collapse completely.

## REFERENCES

1. Bergin, W.C. and W. D. Shipley. 1968. Genital health in the mare: observations concerning the ovulation fossa. *VM/SAC* 63:362-365.
2. Carnevale, E.M., A. O. McKinnon and E. L. Squires. 1988. Effect of preovulatory follicular fluid aspiration upon luteal function in the mare. *Theriogenology* 29:231. (Abstr.).
3. Carnevale, E.M., A. O. McKinnon, E. L. Squires and J. L. Voss. 1988. Ultrasonographic characteristics of the preovulatory follicle preceding and during ovulation in mares. *J. Equine Vet. Sci.* (Accepted).
4. Espey, L.L. 1978. Ovulation. In: *The Vertebrate Ovary: Comparative Biology and Evolution*. Ed. R.E. Jones. Plenum Press, New York, NY.
5. Ginther, O.J. and R. A. Pierson. 1983. Ultrasonic evaluation of the reproductive tract of the mare; principles, equipment, and techniques. *J. Equine Vet. Sci.* 3:195-201.
6. Ginther, O.J. and R. A. Pierson. 1984. Ultrasonic anatomy of equine ovaries. *Theriogenology* 21:471-483.
7. Ginther, O.J. and R. A. Pierson. 1984. Ultrasonic evaluation of the reproductive tract of the mare: ovaries. *J. Equine Vet. Sci.* 4:11-16.
8. Hill, L.M., R. Breckle and C. B. Coulam. 1982. Assessment of human follicular development by ultrasound. *Mayo Clin. Proc.* 57:176-180.
9. McKinnon, A.O. and E. L. Squires. 1987. Ovarian abnormalities. In: *Equine Ultrasound, 5th Annual Short Course Proceedings*. Colorado State Univ. Anim. Reprod. Lab.
10. McKinnon, A.O., E. L. Squires, E. M. Carnevale and G. E. Seidel, Jr. 1988. Heterogenous and xenogenous fertilization of equine oocytes. *Theriogenology* 29:278.
11. McKinnon, A.O., E. L. Squires and J. L. Voss. 1987. Ultrasonic evaluation of the mare's reproductive tract: Part I. *Comp. Cont. Educ. Pract. Vet.* 9:336-345.
12. McKinnon, A.O., M. B. Wheeler, E. M. Carnevale and E. L. Squires. 1987. Oocyte transfer in the mare: preliminary observations. *J. Equine Vet. Sci.* 6:306-309.
13. Neely, D.P. 1983. Equine gestation. In: *Equine Reproduction*. Eds. D.P. Neely, I. K. M. Liu and R. B. Hillman. Veterinary Learning Systems Co. Inc., Princeton Junction, NJ.



14. Parker, W.A. 1971. Sequential changes of the ovulating follicle in the estrous mare as determined by rectal palpation. Proc. Ann. Conf., College of Veterinary Medicine and Biomedical Sciences, Colorado State University, Fort Collins, CO.
15. Pickett, B.W., E. L. Squires and A. O. McKinnon. Procedures for collection, evaluation and utilization of stallion semen for artificial insemination. Colorado State Univ. Anim. Reprod. Lab. Bull. No. 03.
16. Pierson, R.A. and O. J. Ginther. 1985. Ultrasonic evaluation of the corpus luteum of the mare. Theriogenology 23:795-806.
17. Pierson, R.A. and O. J. Ginther. 1985. Ultrasonic evaluation of the preovulatory follicle in the mare. Theriogenology 24:359-368.
18. Prickett, M.E. 1966. Pathology of the equine ovary. Proc. 12th Ann. Conv. A.A.E.P. pp. 145-154.
19. Squires, E.L., J. L. Voss, M. D. Villahoz and R. K. Shideler. 1984. Use of ultrasound in broodmare reproduction. Proc. Equine Ultrasound Short Course, Colorado State Univ. Anim. Reprod. Lab.
20. Witherspoon, D.M. 1975. The site of ovulation in the mare. J. Reprod. Fert. Suppl. 23:329-330.
21. Witherspoon, D.M. and R. B. Talbot. 1970. Ovulation site in the mare. J.A.V.M.A. 157:1452-1459.



## Chapter 6

# FORMATION AND DEVELOPMENT OF THE CORPUS LUTEUM

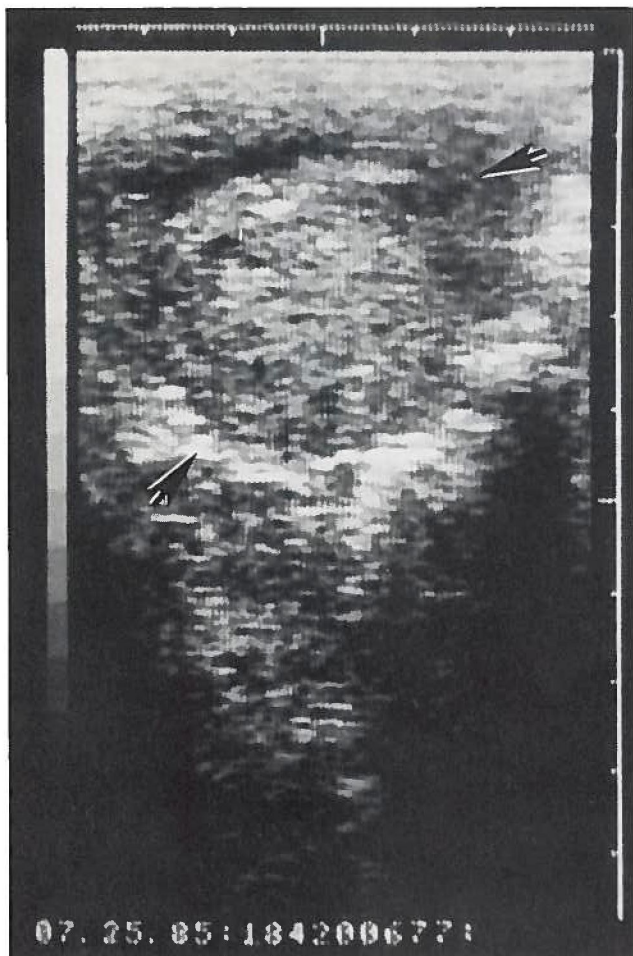
The corpus luteum (CL) is present during two-thirds of the mare's estrous cycle, and for the first 6 mo of pregnancy (4). Progesterone, a primary hormonal product from the CL, has a multitude of functions, including initiation and maintenance of pregnancy. Therefore, methods to evaluate the CL are extremely important. Because of the position of the CL within the ovary, palpation per rectum is of little value for identification and evaluation. However, ultrasonography has been shown to be an effective and accurate means of identifying this structure. Some of the reasons for ultrasonographic evaluation of corpora lutea are:

- a) detect ovulation;
- b) evaluate CL formation;
- c) determine size and characteristics of the CL;
- d) determine if failure of a mare to display estrus is due to prolonged maintenance of a CL or absence of a CL and follicular activity;
- e) distinguish between anovulatory hemorrhagic follicles, luteinized unruptured follicles or CLs; and
- f) determine if a mare has ovulated more than one follicle.

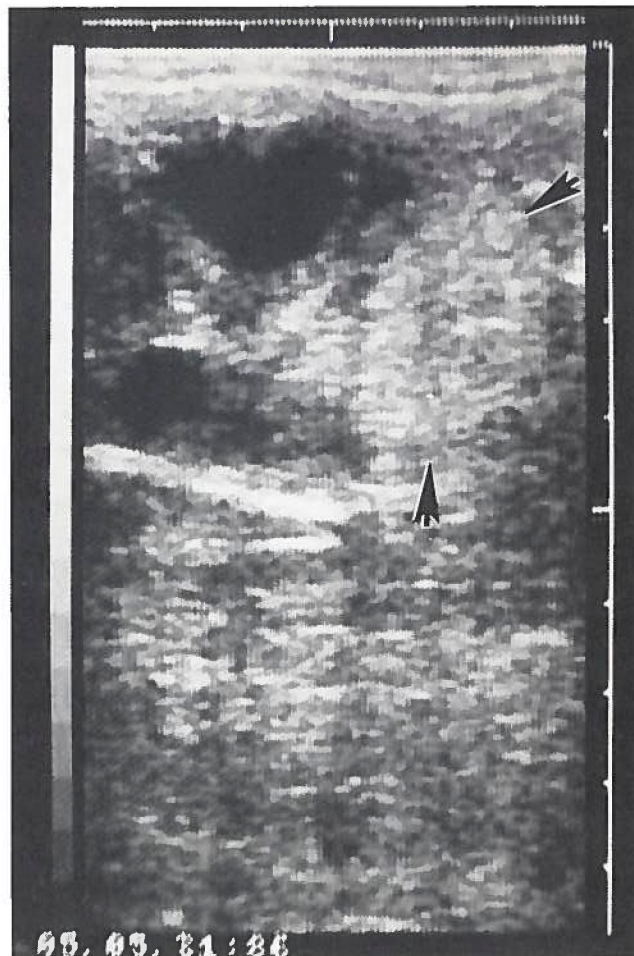
After rupture of the follicle, a corpus hemorrhagicum is formed as a transient phenomenon in the development of the CL in the mare (1). However, it was demonstrated in a recent ultrasonographic study (3) that the equine luteal gland may involve two ultrasonically distinct luteal morphologies. Both types of luteal structures are uniformly echogenic on day 1. One type, classified as uniformly echogenic, is seen in approximately 50% of the CLs and the percent of echogenicity remains constant for the duration of diestrus (Figures 6-1 to 6-4). The other, classified as centrally nonechogenic (corpus hemorrhagicum) develops a nonechogenic center on day 0 or day 1 (Figures 6-5 to 6-7). The percentage of CLs considered echogenic was lowest on day 3, and increased linearly throughout diestrus. In a subsequent study (5), the time

required for accumulation of fluid and formation of central clots (nonechogenic areas) was studied with ultrasonography. Examinations were conducted at 15-min intervals for the first 2 hrs after ovulation, again at 8 hrs and thereafter at 12-hr intervals for 5 days. In 2 of 10 mares, a nonechogenic area did not develop within the luteal gland, and in one mare only a small central area (0.5 cm<sup>2</sup>; 1.20 in<sup>2</sup>) was detected at 20 and 32 hrs, and not thereafter. In five mares, a nonechogenic central area developed within the luteal gland after the expulsion of follicular fluid. The size of the nonechogenic area varied from 0.5 to 11.6 cm<sup>2</sup> (.20 to 4.57 in<sup>2</sup>). For those mares with central nonechogenic areas, echogenic lines within the central area were detected. These were attributed to clotting and fibrinization of the contents. From the results of data collected in our laboratory (2), it appeared that, when CL evaluations were made on days 5 to 7 post-ovulation, the number of centrally nonechogenic CLs was lower (9.2%; n = 192 cycles) than that reported previously (3). In addition, the incidence of at least one centrally nonechogenic CL increased with double ovulations (36%; n = 23 double ovulations). However, from the results of more recent data, a higher percentage of centrally nonechogenic CLs was observed. This is dependent, to some extent, upon days post-ovulation (Table 6-1). Comparative studies, on duration of diestrus, concentrations of progesterone and fertility data should be conducted to determine categorically if both morphologic types of CLs are normal.

Ginther (1) reported on the accuracy of detecting a CL with ultrasonography. Location of the CL was established by daily palpation per rectum. Ultrasonographic examinations were done by another technician unaware of the site of ovulation. The ultrasonographer recorded location of the CL, or indicated that one was not found or that there was uncertainty about identification. The ultrasonographer was correct in 88% of his examinations conducted on days 0 to 14 post-ovula-



**Figure 6-1.** Uniformly echogenic CL on day 0 (arrows).



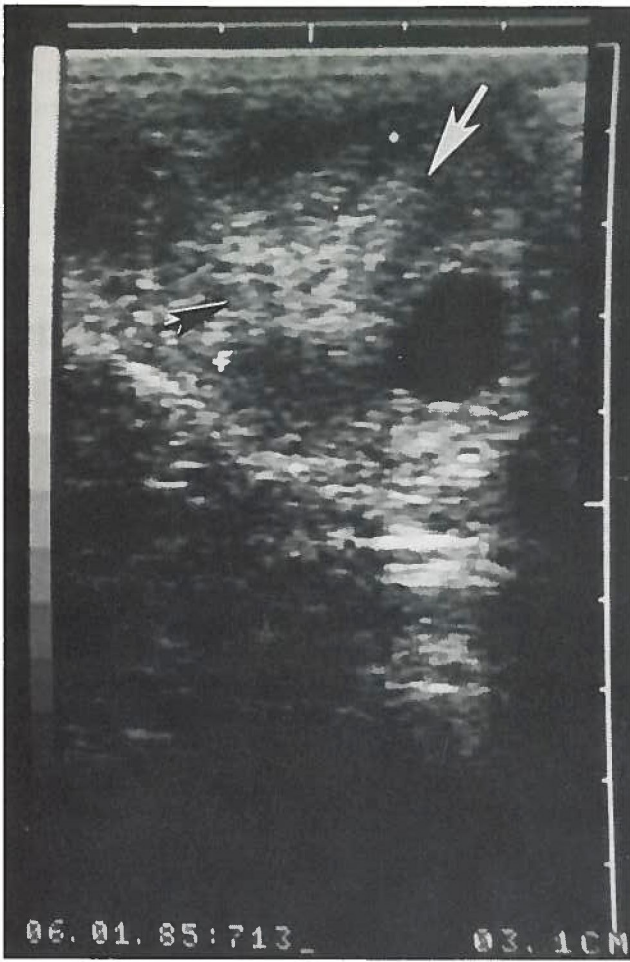
**Figure 6-2.** Uniformly echogenic CL on day 7 (arrows).

tion. In the remaining 12%, the ultrasonographer recorded the locations as uncertain. In addition, in all 12 mares that were in estrus, the location of the CL was recorded as uncertain. From these results it appears that ultrasonography can be used to visualize a CL, even if the site of ovulation is unknown. Therefore, ultrasonography is an extremely valuable diagnostic tool for determining the presence or absence of the CL.

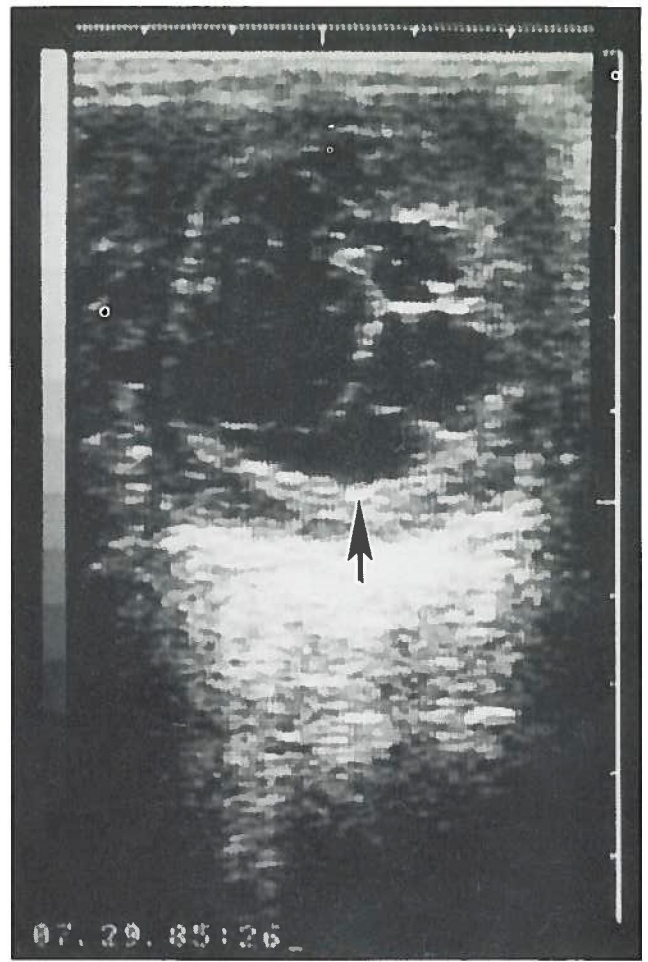
Visualization of the CL is much easier and more accurate with a 5 MHz transducer and a quality ultrasound scanner than a 3 MHz machine. Presented in Figures 6-1 to 6-7 is a series of ultrasonographic images and gross characteristics of CLs at various stages of development. A 5 MHz transducer was used to obtain these images. The ultrasonographic image is affected by amount of blood within the CL. Blood is nonechogenic, whereas luteal cells are echogenic. Generally, luteinization begins on the periphery of the structure and migrates medially. Normally, as the CL ages, blood is resorbed and a uniformly echogenic, luteal structure develops. Fibrin-like material can separate the blood clot into areas of dark, nonechogenic sections containing red blood cells, plasma and(or) perhaps follicular fluid. Lighter areas may be indicative of fibrin strands

or developing luteal tissue. Although the ultrasonographic properties of the mature CL are similar to ovarian stroma, a CL can be distinguished by its defined borders. Ginther (1) found that the ultrasonographic texture of the luteal gland was characterized by an echo pattern indicative of loosely organized, well-vascularized tissue, whereas ovarian stroma generally yielded brighter echoes in a pattern representative of dense tissue. Also, the majority of CLs had a distinct mushroom or gourd shape.

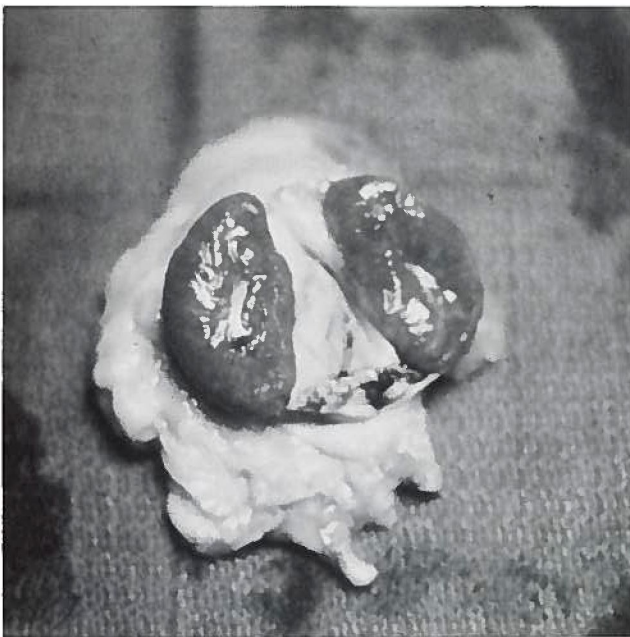
In glands classified as centrally nonechogenic, the nonechogenic area was first visible on day 0 or 1 post-ovulation. These types of luteal structures were at their greatest echogenicity on day of ovulation (75 to 100% of the gland). This probably was due to the ultrasonographic properties of collapsed follicular walls. The nonechogenic area, which was the central cavity, enlarged over days 1 to 3 due to enlargement of the blood clot (Figure 6-5). As the blood clot was resorbed, that portion of the structure that was echogenic increased throughout the remaining portion of the cycle (Figure 6-6). In contrast, luteal glands that were characterized as uniformly echogenic did not change (Figure 6-3) throughout the cycle, except the brightness (gray scale) changed throughout the life of the CL.



**Figure 6-3.** Uniformly echogenic CL on day 14 (arrows).



**Figure 6-5.** Corpus hemorrhagicum or centrally nonechogenic CL (arrow) on day 1 post-ovulation.



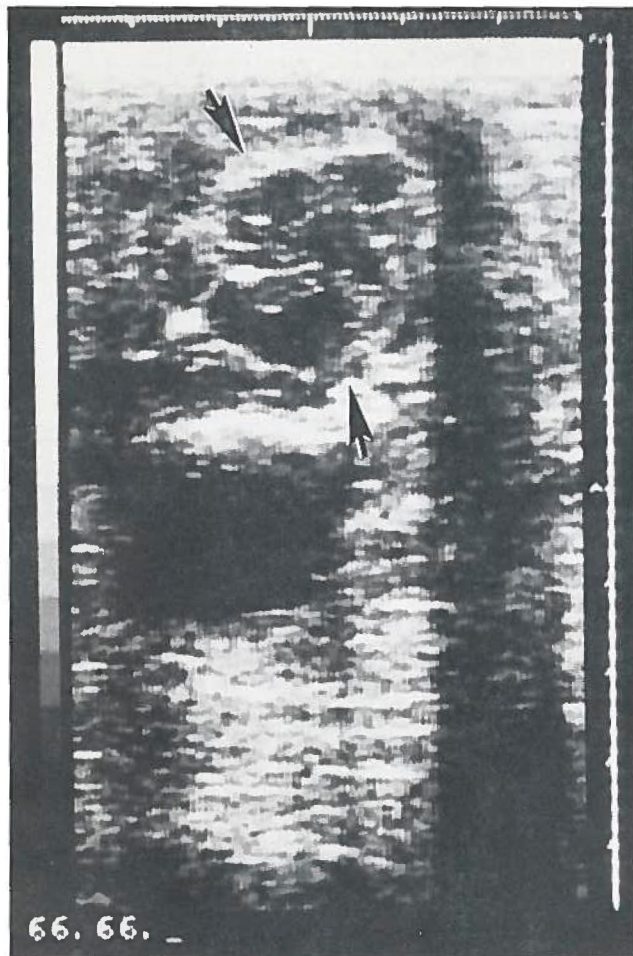
**Figure 6-4.** Gross characteristics of a CL that would be uniformly echogenic when visualized with ultrasonography.

**Table 6-1. Percentage of Echogenic and Nonechogenic CL Visualized with Ultrasonography**

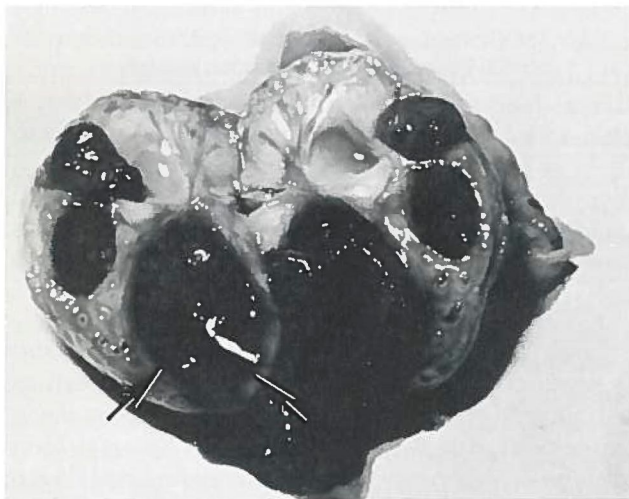
Characteristic	Day post-ovulation <sup>a</sup>								
	0	1	2	3	4	5	6	7	8
Echogenic	76	63	54	46	64	71	75	56	100
Nonechogenic	24	37	46	54	36	29	25	44	0
Number of mares observed	62	16	69	13	22	93	12	16	6

<sup>a</sup> Ovulation is defined as day 0.

Ginther (1) demonstrated that both types of glands change in echogenicity throughout the diestrus period. Initially, the CL is highly echogenic on day of ovulation (Figure 6-1). At this time, it is easiest to identify. The echogenicity decreases over the first 6 days of diestrus, remains at a minimum level for several days during the middle of diestrus, then increases over days 12 to 16. The very bright, hyperechogenic echoes on day 0 may be due to apposition of collapsed follicular walls. There was also an increase in brightness of the CL during the time of CL regression. These ultrasonographic changes are apparently indicative of changes in luteal hemodynamics. They may be indicative of changes in patterns of blood flow within the CL and changes in tissue density.



**Figure 6-6.** Corpus hemorrhagicum on day 9 post-ovulation. The borders of the luteal structure are designated by arrows.



**Figure 6-7.** Gross characteristics of a developing corpus hemorrhagicum, which appears as a centrally nonechogenic CL when visualized with ultrasonography.

With experience, the practitioner can become very accurate at using ultrasonography to confirm ovulation and to detect the presence of a CL. Ultrasonography can also be used to diagnose pseudopregnant mares. A persistent CL and absence of an embryonic vesicle are evidence of a pseudopregnant mare. Once these mares are identified, prostaglandins can be safely given to induce estrus. Echogenicity of this structure can be used to determine to some extent the age of a CL. Hyperechogenicity is typical of the first few days after ovulation or during CL regression. The first few days usually can be distinguished from the last few days on the basis of gland size. In the middle of diestrus, the CL will be lower on the gray scale than either at the beginning or the end. However, the structure will be at maximal size during the middle of diestrus. If the CL contains a central nonechogenic cavity, the ratio of luteal tissue to blood clot and degree of organization of the clot can be of assistance in estimating age of the gland. The blood clot develops during the first few days, then progressively becomes more organized and proportionally smaller. It is hoped that with the advent of newer and better equipment, the dynamics of change in the CL will be more easily distinguished.

#### REFERENCES

1. Ginther, O.J. 1986. Ultrasonic Imaging and Reproductive Events in the Mare. Equiservices, Cross Plains, WI.
2. McKinnon, A.O., E.L. Squires and J.L. Voss. 1987. Ultrasonic evaluation of the mare's reproductive tract: Part I. *Comp. Cont. Educ. Pract. Vet.* 9:336-345.
3. Pierson, R.A. and O.J. Ginther. 1985. Ultrasonic evaluation of the corpus luteum of the mare. *Theriogenology* 23:795-806.
4. Squires, E.L., R.H. Douglas, W.P. Steffenhagen and O.J. Ginther. 1974. Changes during the estrous cycle and pregnancy in mares. *J. Anim. Sci.* 38:330-338.
5. Townson, D.H. and O.J. Ginther. 1988. The development of fluid-filled luteal glands in mares. *Anim. Reprod. Sci.* (In press).

## Chapter 7

# OVARIAN ABNORMALITIES

### Introduction

The ability to noninvasively examine the mare's ovaries permits diagnosis of various forms of ovarian abnormalities and pathology. Some ovarian abnormalities that have been recognized with ultrasonography are: a) multiple, preovulatory follicles; b) anovulatory hemorrhagic follicles; c) luteinized, unruptured follicles; d) persistent CLs; and e) various ovarian tumors and periovarian cysts.

### Multiple Preovulatory Follicles

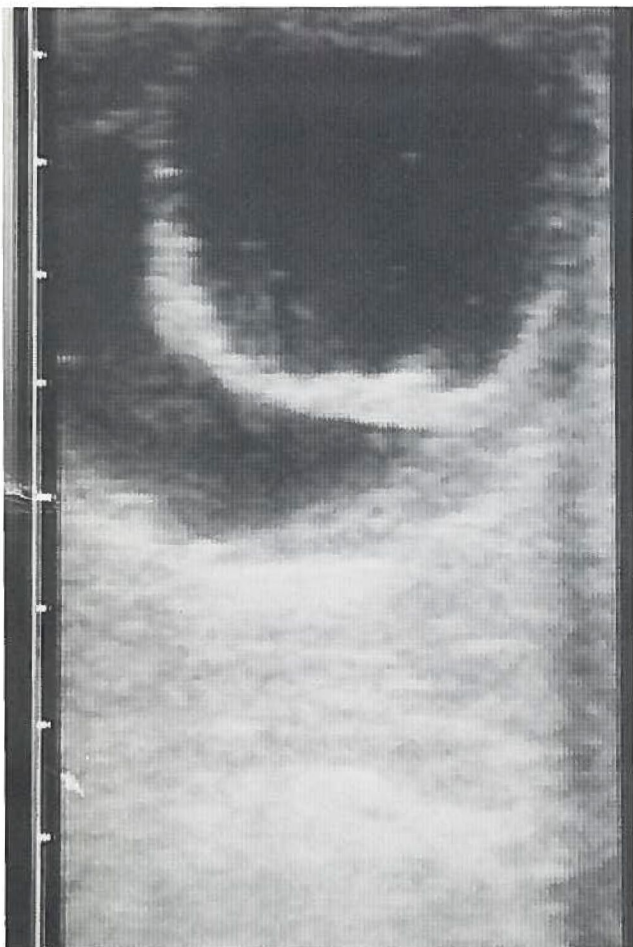Since the mare normally ovulates only one follicle during each estrous cycle (1), multiple ovulations may be considered an abnormality. Breed influences the incidence of multiple ovulation. For example, Thoroughbreds, warm bloods and draft mares have been shown to have the highest incidence of multiple ovulation; whereas, Quarter Horses, Appaloosas and ponies have the lowest incidence with Standardbreds being intermediate (2). Multiple, preovulatory follicles (Figure 7-1) or ovulations (Figure 7-2) may be particularly difficult to detect by rectal examination, especially when they are in close apposition on one ovary. In a study conducted in our laboratory (14), more embryos were obtained from multiple ovulating mares that bilaterally ovulated than from those in which multiple ovulation was unilateral. Multiple ovulations should be encouraged, when ultrasonography is available to eliminate one of two developing vesicles at 14 days, because multiple ovulations increase the probability of conception.

The ability to collect and transfer multiple embryos from a donor mare has the potential of improving efficiency of an equine embryo transfer program. A study was performed at our laboratory (14) to evaluate viability of embryos collected from naturally and induced multiple ovulating versus single, naturally ovulating mares. Recovery of embryos from single-ovulating mares was 53% compared to 106% for naturally double-ovulating mares. Pregnancy rate 50 days

after surgical transfer was 68 and 129%, respectively. Treatment of normally single-ovulating mares with equine pituitary extract resulted in the recovery of two embryos per donor compared to 0.65 for controls(14). Nonsurgical pregnancy rates for embryos collected from superovulated mares were identical to those obtained for untreated controls (39%). Since viability of multiple embryos, collected from spontaneously and induced multiple-ovulating mares, was equal to that of embryos from single-ovulating mares, collection and transfer of embryos from these mares increased the efficiency of equine embryo transfer.

### Anovulatory Hemorrhagic Follicles

Anovulatory hemorrhagic follicles (AHF) are the result of preovulatory follicles growing to an unusually large size (70 to 100 mm; 2.75 to 3.94 in), failing to ovulate, then filling with blood and gradually receding (Figures 7-3 and 7-4). Ultrasonography has been used in our laboratory to confirm this condition in mares when it was first identified as an abnormality by rectal palpation. This phenomenon may be recognized as an entity distinct from a corpus hemorrhagicum by its size and by ultrasonographic characteristics. The blood in an AHF is distinctly echogenic, whereas normal development of the corpus hemorrhagicum results in a generally nonechogenic central blood clot (15 to 35 mm [.59 to 1.38 in] in diameter). However, both may have criss-crossing fibrin-like strands. The formation of luteal tissue around the periphery of an AHF follicle is rare or minimal. We have noted in some mares, development and subsequent ovulation during the same estrous cycle of another follicle after formation of an AHF. In these mares, behavioral signs of estrus persisted throughout an unusually long cycle of approximately 12 days, or 5 days after recognition of an AHF. Unfortunately, serum progesterone has not been measured in these animals. It is possible that AHFs are the previously reported "autumn" follicles(12), since most have occurred toward the end of the ovulatory season.



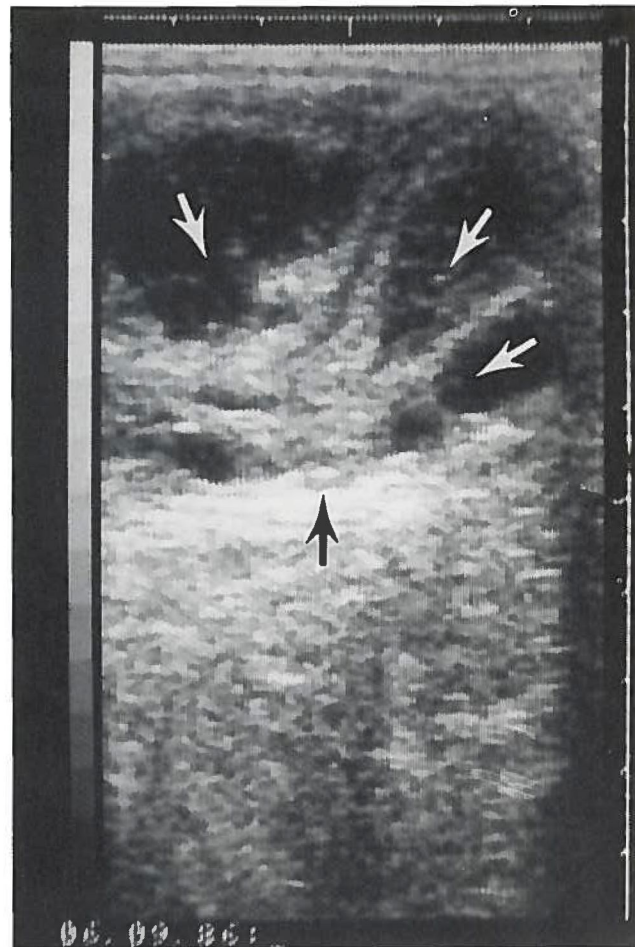
**Figure 7-1.** Ultrasonographic image of double preovulatory follicles.

Perhaps AHFs develop because of insufficient stimulus for ovulation from gonadotropic releasing **hormones**. After the last ovulation of the year, mares may develop a large follicle at the expected time, but the follicle does not ovulate and the mare enters the anovulatory season (1).

### Luteinized, Unruptured Follicles

Although anovulatory estrous periods are very common during the anovulatory season, they are rare during the ovulatory season (1). An incidence of 3.1% was reported in Thoroughbreds and Quarter Horses (6), and even these may have been misdiagnosed because palpation was used (Chapter 6).

Luteinized, unruptured follicles have been reported in women (5) and mice, but not in nonpregnant mares. This phenomenon is thought to be associated with reproductive senility. In 1986, a study (8) was initiated to recover embryos from oviducts of old, infertile mares. On some occasions, when the oviducts were flushed 2 days post-ovulation, no embryos or unfertilized ova were recovered and, from close examination of the ovulation fossa, it appeared that recent ovula-



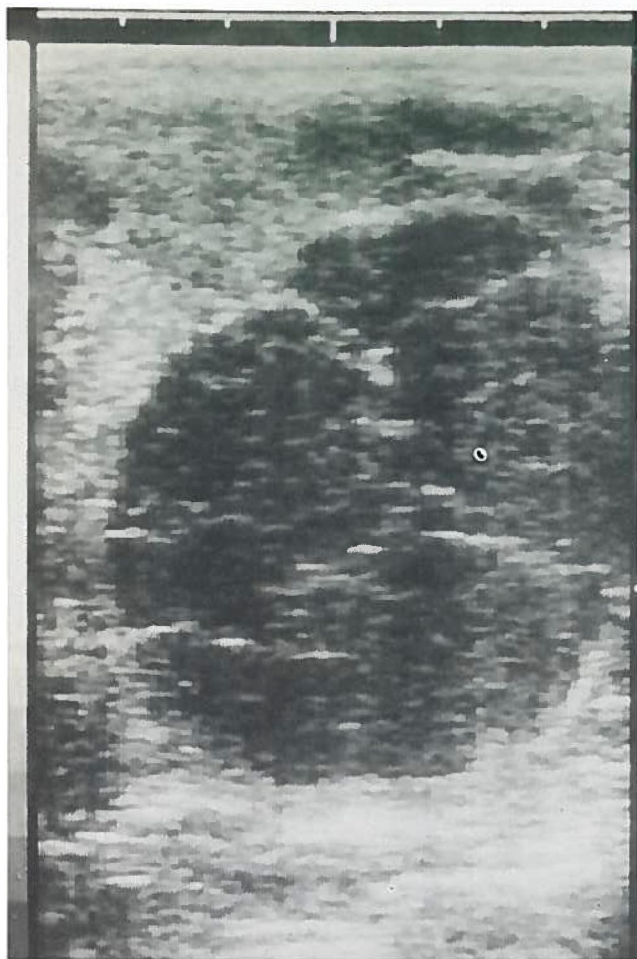**Figure 7-2.** Ultrasonographic image of a triple ovulation (white arrows). All ovulations have tracts to the ovulation fossa (black arrows).

tion had not occurred. Surgical removal of two ovaries from two mares confirmed that ovulation into the ovulation fossa had not occurred and, from prior ultrasonographic examination, it appeared that an atypical corpus hemorrhagicum had formed (Figure 7-5). Both mares ceased displaying signs of estrus within one day of the suspected ovulation. Concentrations of progesterone levels were not available. These structures may have been luteinized, unruptured follicles similar to those in women and mice and may be associated with senility. Luteinization without ovulation occurred quite commonly in pregnant mares in association with formation of secondary CLs (13).

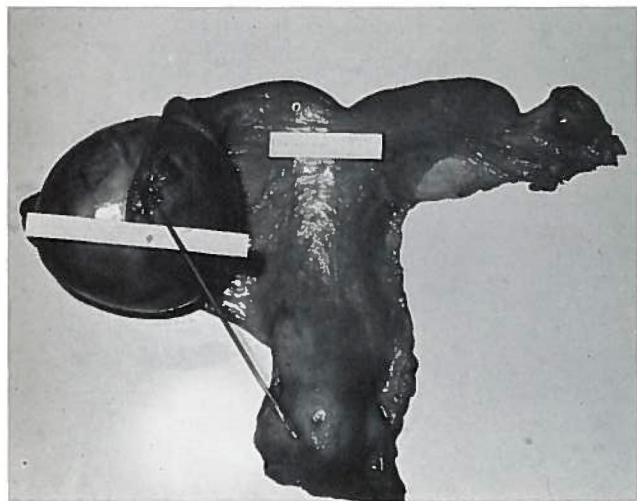
### Prolonged Maintenance of the Corpus Luteum

Rectal palpation of the CL, although possible on occasion (9), is generally unrewarding. Prolonged maintenance of the CL, resulting in pseudopregnancy (12) can be differentiated from an anovulatory or anestrus condition with a 5 MHz transducer. The CL is first visible on day of ovulation (day 0) as a strongly echogenic, circumscribed mass of tissue(10). The echogenicity gradually decreases throughout diestrus.

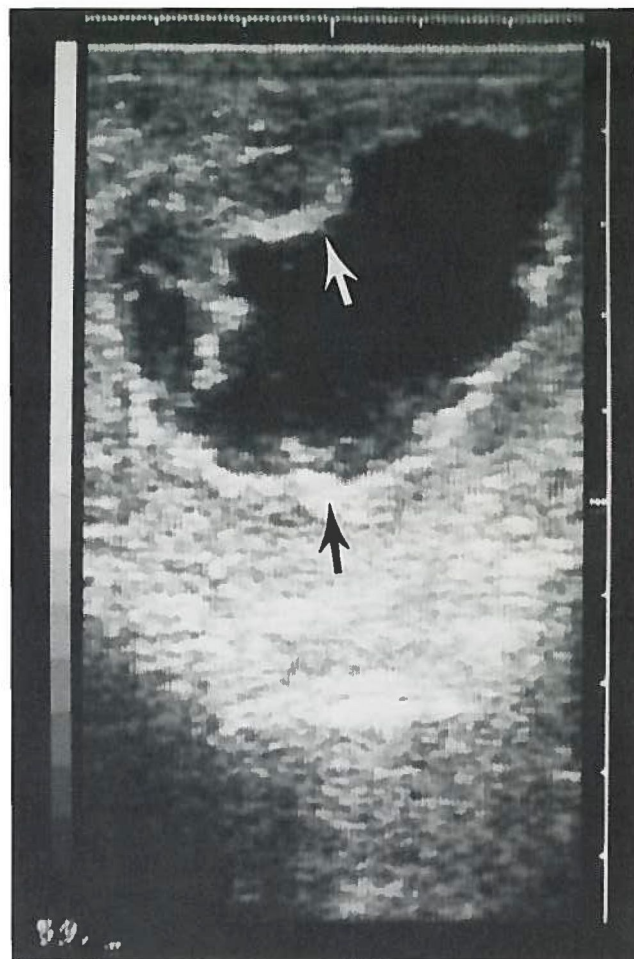




**Figure 7-3.** Ultrasonographic image of an anovulatory, hemorrhagic follicle.



**Figure 7-4.** Gross post-mortem characteristics of an anovulatory, hemorrhagic follicle. (Courtesy of Dr. V. E. Osborne).

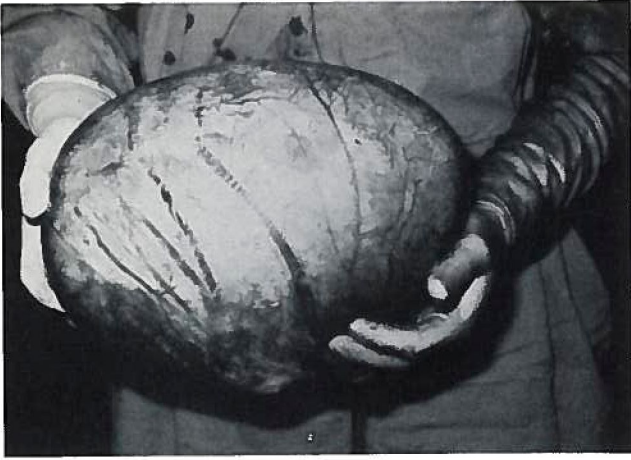


**Figure 7-5.** Ultrasonographic image of a luteinized, unruptured follicle. Note extreme irregularity and thickening of the follicular wall indicative of luteal tissue (arrows).

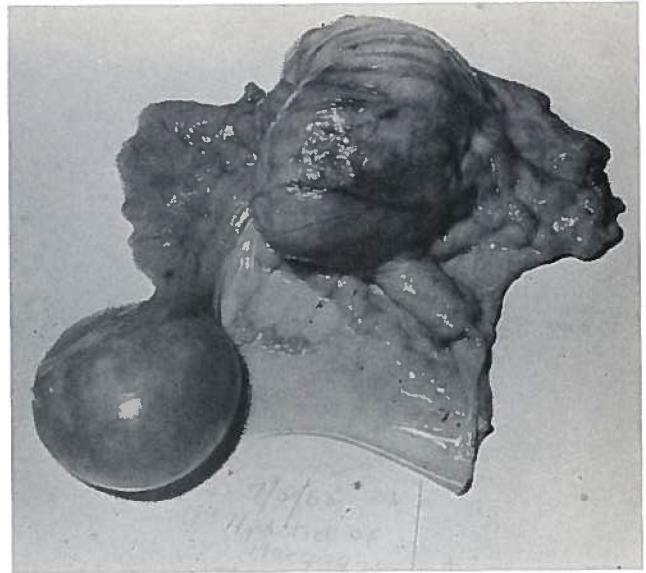
However, just prior to regression of the CL the echogenicity decreases. This may reflect changes in luteal hemodynamics. In one study (10), the CL could be observed for a mean of 17 days ( $n = 55$ ). On occasion, the presence of a CL may be seen as a circumscribed, highly echogenic area of tissue in the ovary in mares that failed to return to estrus at the expected time. Prolonged maintenance of the CL is more commonly recognized in normally cycling mares that have been bred. Generally, the mare fails to return to estrus at the expected time, even though she is not pregnant. Perhaps pregnancy is initiated and the embryo prevents secretion of prostaglandin F<sub>2</sub>-alpha prior to succumbing to EED. In one study(4), removal of the conceptus early in pregnancy (days 7 to 11) resulted in return to estrus at the expected time or slightly earlier, while removal later (days 14 to 16) resulted in prolonged maintenance of the CL, or pseudopregnancy.

### Ovarian Neoplasia

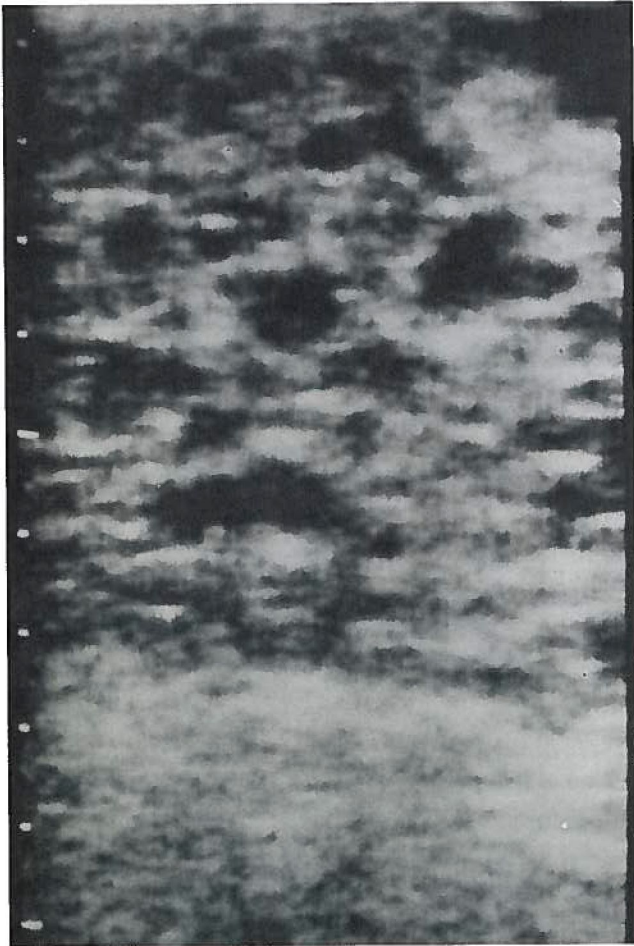The incidence of ovarian tumors is relatively common in mares when compared to other domestic species. The incidence of ovarian tumors in horses has



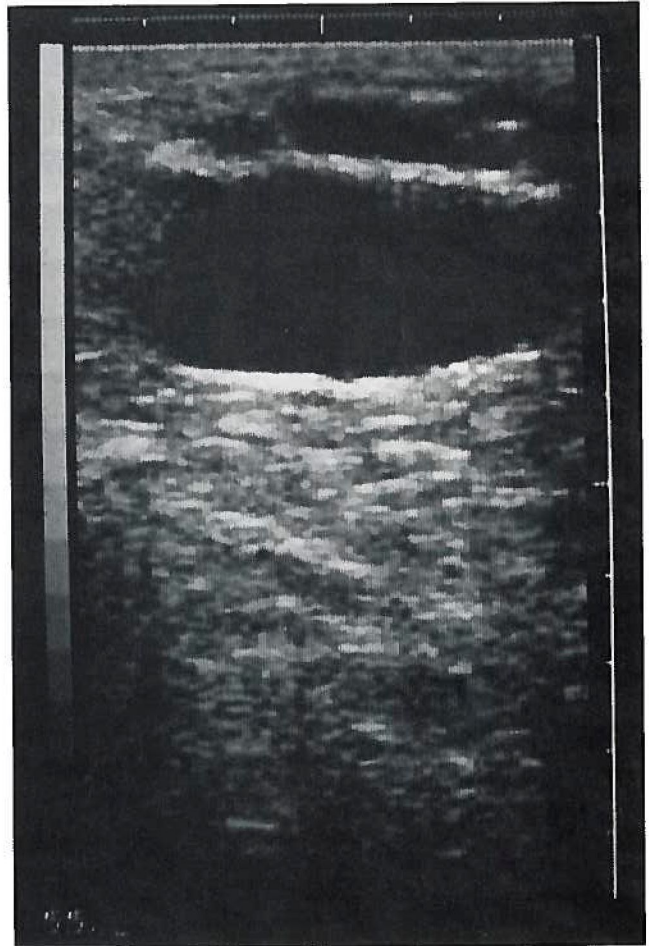
**Figure 7-6.** Gross characteristics of a granulosa theca cell tumor.



**Figure 7-8.** Gross characteristics of a cyst or Hydatid of Morgagni. (Courtesy of Dr. V. E. Osborne).



**Figure 7-7.** Ultrasonographic image of a granulosa theca cell tumor.



**Figure 7-9.** Ultrasonographic image of a Hydatid of Morgagni.

been reported to be as high as 5.6% of all neoplasms (11). By far the two most common tumors are the granulosa theca cell tumor (Figures 7-6 and 7-7) and the teratoma (7). Granulosa theca cell tumors are usually large, benign, steroid-producing tumors often associated with behavioral changes and poor reproductive performance. The most common history is a barren, anestrus mare. Other clinical signs are intermittent or continuous estrus, nymphomania or stallion-like behavior (11). The ultrasonographic characteristics of granulosa theca cell tumors will vary. Gross characteristics may be solid or cystic. Palpation may reveal a smooth surface, a knobby, hard surface, or sometimes a soft surface with obvious follicular development. The unaffected ovary is usually inactive. Surgical excision is the treatment of choice, and most mares will return to normal reproductive performance within 2 to 16 mo after surgery.

Ovarian teratomas are benign and nonsecretory. The tumors arise from germ cells and are usually nondescript, epithelial tissue, but may contain cartilage, skin, bone, hair, nerves, sebaceous material and even teeth. They may be solid or cystic. They generally do not interfere with fertility and are most commonly discovered during routine rectal palpation, unless they become extremely large and affect other organs.

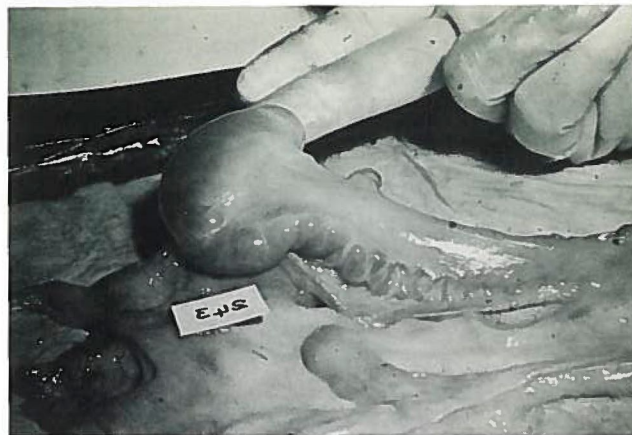Ultrasonographic examination may help differentiate between neoplasia and other large nonneoplastic structures, such as anovulatory, hemorrhagic follicles, or an ovary during the transitional period with multiple, non-dominant follicles. However, in general, definite diagnosis will rely on histological or gross examination of the affected ovary.

### Periovarian Cysts

Embryonic vestiges and cystic accessory structures associated with the ovary and oviduct are quite common in mares. These cysts, although often small, may occasionally be confused with an ovarian follicle. Rectal palpation in these circumstances is generally more accurate than ultrasonography in determining whether the structure is part of the ovary. Small fimbrial cysts (< 10 mm; .39 in) probably do not cause infertility. On occasion, cystic remnants of the mesonephric tubules and ducts may grow quite large (30 to 40 mm [1.18 to 1.57 in] in length and 10 to 15 mm [.39 to .59 in] in diameter). One such recognized cyst is the *Hydatid of Morgagni* (Figures 7-8 and 7-9). This type of cyst has been diagnosed with ultrasonography. However, it is sometimes difficult to distinguish between ovarian follicles and periovarian cysts.

### Miscellaneous Ovarian Abnormalities

Hydrosalpinx is not common in mares (3), but since it is a fluid-filled structure (Figure 7-10), it can be detected with ultrasonography. Definitive diagnosis may require laparoscopy or exploratory surgery.



**Figure 7-10.** Gross characteristics of a hydrosalpinx. (Courtesy of Dr. V. E. Osborne).


Information on other types of ovarian abnormalities is just beginning to be obtained. We have identified cystic, follicular structures that have not ovulated. Some have regressed while others have persisted. Only careful documentation and hormonal analyses will elucidate the etiologies of and treatments for many of these previously unidentified abnormalities.

### REFERENCES

1. Ginther, O.J. 1979. Reproductive Biology of the Mare: Basic and Applied Aspects. Equiservices, Cross Plains, WI.
2. Ginther, O.J. 1982. Twinning in mares: a review of recent studies. *J. Equine Vet. Sci.* 2:127-135.
3. Ginther, O.J. 1986. Ultrasonic Imaging and Reproductive Events in the Mare. Equiservices, Cross Plains, WI.
4. Hershman, L. and R. H. Douglas. 1979. The critical period for the maternal recognition of pregnancy in pony mares. *J. Reprod. Fert. Suppl.* 27:395-401.
5. Holtz, G., H. O. Williamson, R. S. Mathur, S. C. Landgrebe and E. E. Moore. 1985. Luteinized unruptured follicle syndrome in mild endometriosis. Assessment with biochemical parameters. *J. Reprod. Med.* 30:643-645.
6. Hughes, J.P., G. H. Stabenfeldt and J. W. Evans. 1972. Clinical and endocrine aspects of the estrous cycle of the mare. *Proc. 18th Ann. Conv. A.A.E.P.* pp. 119-151.
7. Jubb, K.V.F. and P. C. Kennedy. 1970. The female genital system. In: *Pathology of Domestic Animals*. Eds. K.V.F. Jubb and P.C. Kennedy, 2nd ed., Vol 1. Academic Press, New York, NY.
8. McKinnon, A.O., G. W. Trotter, E. M. Carnevale and E. L. Squires. 1988. Oviductal embryo recovery from infertile and fertile mares. (Submitted).
9. Parker, W.A. 1971. Sequential changes of the ovulating follicle in the estrous mare as determined by rectal palpation. *Proc. Ann. Conf. College of Veterinary Medicine and Biomedical Sciences, Colorado State University, Fort Collins, CO.*

10. Pierson, R.A. and O. J. Ginther. 1985. Ultrasonic evaluation of the corpus luteum of the mare. *Theriogenology* 23:795-806.
11. Pugh, D.G., J.M. Bowen and E. M. Gaughan. 1985. Equine ovarian tumors. *Comp. Cont. Educ. Pract. Vet.* 7:S710-716.
12. Roberts, S.J. 1971. *Veterinary Obstetrics and Genital Diseases*. 2nd ed. Ithaca, NY.
13. Squires, E.L., R. H. Douglas, W. P. Steffenhagen and O. J. Ginther. 1974. Ovarian changes during the estrous cycle and pregnancy in mares. *J. Anim. Sci.* 38:330-338.
14. Squires, E.L., A. O. McKinnon, E. M. Carnevale, R. Morris and T. M. Nett. 1987. Reproductive characteristics of spontaneous double and single ovulating mares and superovulated mares. *J. Reprod. Fert. Suppl.* 35:399-403.

RECEIVED  
DEC 11 1952  
COLLEGE OF AGRICULTURE  
State Publications Library



RECEIVED  
DEC 11 1952  
COLORADO STATE LIBRARY